



저작자표시-비영리-변경금지 2.0 대한민국

이용자는 아래의 조건을 따르는 경우에 한하여 자유롭게

- 이 저작물을 복제, 배포, 전송, 전시, 공연 및 방송할 수 있습니다.

다음과 같은 조건을 따라야 합니다:



저작자표시. 귀하는 원저작자를 표시하여야 합니다.



비영리. 귀하는 이 저작물을 영리 목적으로 이용할 수 없습니다.



변경금지. 귀하는 이 저작물을 개작, 변형 또는 가공할 수 없습니다.

- 귀하는, 이 저작물의 재이용이나 배포의 경우, 이 저작물에 적용된 이용허락조건을 명확하게 나타내어야 합니다.
- 저작권자로부터 별도의 허가를 받으면 이러한 조건들은 적용되지 않습니다.

저작권법에 따른 이용자의 권리는 위의 내용에 의하여 영향을 받지 않습니다.

이것은 [이용허락규약\(Legal Code\)](#)을 이해하기 쉽게 요약한 것입니다.

[Disclaimer](#)

A Thesis for the Degree of Master

Correlations between Vertebral Heart
Score and Heart to Single Vertebra
Ratio in Brachycephalic
“Screw-tailed” Dog Breeds

Yejin Kim

Department of Veterinary Medicine

The Graduate School

Jeju National University

February 2024

Correlations between Vertebral Heart Score and Heart to Single Vertebra Ratio in Brachycephalic “Screw-tailed” Dog Breeds

A Thesis submitted to the graduate school of
Jeju National University in partial fulfillment of
the requirements for the degree of Master of Veterinary
medicine under the supervision of
Hyunjung Park

The thesis for the degree of Master of Veterinary medicine
by **Yejin Kim**
has been approved by the dissertation committee.

2023. 11

Chair [Jongtae Cheong] _____

Member [Hyunjung Park] _____

Member [Joo Myoung Lee] _____

Correlations between Vertebral Heart Score and Heart to Single Vertebra Ratio in Brachycephalic “Screw-tailed” Dog Breeds

Yejin Kim

Department of Veterinary Medicine
The Graduate School Jeju National University

Abstract

Radiographic image is a good approach method for diagnosis of cardiac disease. Among a number of measuring cardiac silhouette technique, vertebral heart score (VHS) is widely known system. However, there is limitation when patients with congenital thoracic vertebral disease. To make up for deficiency, heart-to-single vertebra ratio (HSVR) is suggested. The purpose of this study was to prove correlation between HSVR and VHS at screw-tailed brachycephalic breeds. This study was examined retrospectively by three independent observers about patients who came to Jeju National University and 3 local animal hospital during 2015-2023. Between sampled data, dogs with vertebral fusion with multiple body was excluded. 72 data of five screw tailed breeds were examined in analysis. The data sorted by two different groups. Normal group included the screw tailed brachycephalic breed without vertebral body formation defeats. Abnomral group included the screw tailed brachycephalic breed with vertebral body formation defeats.

The Lin's concordance correlation coefficient (CCC) demonstrated moderate agreement between HSVR and VHS in normal group (0.907 to 0.936), with acceptable mean differences (± 0.338 to ± 0.397). Lin's CCC in the abnormal group indicated poor agreement between HSVR and VHS in abnormal group (0.093 to 0.518), with larger mean differences (± 1.427 to ± 4.576). Analysis of Lin's CCC between individual HSVR range in the abnormal group showed poor agreement between each HSVR range between T4, T5, T6, T7, and T8 (0.079 to 0.557).

In conclusion, HSVR can be alternative method of VHS in normal group, which doesn't have any thoracic vertebral abnormalities. Though, HSVR cannot produce a better result than VHS method in congenital thoracic vertebral abnormalities in screw-tailed brachycephalic breeds.

Keywords: heart to single vertebral ratio (HSVR), vertebral heart score (VHS), screw tailed, brachycephalic, dog

단두종의 "나선형 꼬리" 호발 품종에서 Vertebral Heart Score과 Heart to Single Vertebra Ratio 간의 상관관계

김예진

제주대학교 대학원 수의학과

초록

방사선 이미지는 심장 질환 진단에 손쉬운 접근 방법이다. 여러 가지 심음영 크기 측정 기술 중에서 vertebral heart score (VHS)는 널리 알려진 방법이다. 그러나 선천적인 흉추 추체 질환을 가진 환자의 경우 정확한 VHS 측정에 한계가 존재한다. 이 결함을 보완하기 위해 Heart-to-single vertebral ratio (HSVR)가 제안되었다. 본 연구의 목적은 단두종에서 HSVR과 VHS 간의 상관 관계를 입증하는 것이다.

이 연구는 2015년부터 2023년까지 제주 국립 대학교 및 3개 지역 동물 병원에 내원한 환자들을 대상으로 하는 후향적인 연구로 진행되었다. 수집된 데이터 정보 중 추체가 다수로 이어진 block vertebra를 가진 환자는 제외되었다. 총 5종의 72마리의 환자가 분석되었고, 이 데이터는 정상과 비정상 두 가지 그룹으로 나뉘었다.

Lin's concordance correlation coefficient (CCC)는 정상 그룹에서 HSVR과 VHS 간에 중간 정도의 일치도를 보여주었다 (0.907 to 0.936), Bland-Altman plot은 허용 가능한 표준 편차를 나타냈다(± 0.338 to ± 0.397). 비정상 그룹의 Lin's CCC는 HSVR과 VHS 간에 낮은 일치도를 나타냈으며(0.093 to 0.518), Bland-Altman 플롯은 더 큰 표준 편차를 보여주었다(± 1.427 to ± 4.576). 비정상 그룹에서 HSVR 간의 Lin's CCC 분석에서 낮은 일치도를 나타냈다(0.079 to 0.557).

결론으로, HSVR은 screw tail을 가진 단두종에서 척추 질환이 없을 때에는 VHS를 대체할 만한 방법이지만, screw tail을 가진 단두종에서 척추 질환이 있을 때에는 VHS를 대체할 만한 방법이 아닌 것으로 확인되었다.

Keywords: heart to single vertebral ratio (HSVR), vertebral heart score (VHS), screw tailed, brachycephalic, dog

Contents

I. Introduction	1
II. Material and Methods	3
III. Results	7
IV. Discussion	17
V. Conclusion	20
VI. Reference	21

Introduction

The mortality rate of congenital heart diseases increased due to increased expectancy of life. To prevent and diagnose cardiac diseases, radiographic data serves as a valuable diagnostic tool for identifying signs such as anomalous size, silhouette of pulmonary vessels, and existence of pulmonary oedema or pleural effusion. These manifestations may indicate the presence of congenital vasculocardiac diseases.¹ The shape and size of the cardiac silhouette became the basic protocols of radiographic technique, to determine cardiac disease such as myxomatous mitral valve disease.^{2,3,4} Bucheler and Buchanan(1995) designed vertebral heart score (VHS), the method of cardiac silhouette by comparing the heart scale with 4th thoracic vertebral body.² This method is the most used technique due to simple application and accuracy. To these day, there are a number of studies about the VHS method.^{6,7,8,9}

To calculate the cardiac silhouette in a radiographic image, there are various ways of measurement beside the VHS.^{5,10} Intercostal space is one of the methods to measure the volume of cardiac in approximately. The thoracic inlet heart size is the other approach to measure cardiac silhouette.¹⁰ Thoracic inlet heart size is the way to normalize the heart size by using the thoracic inlet length. Another method to measure the volume of cardiac is the use of VD or DV radiographic view, than lateral view.⁵ By comparing the length of T4 and the sum of long and short axis of the cardiac silhouette on VD or DV view, is one of the ways to calculate the cardiac.

Though, those methods have limitations with the cases of the vertebral alteration patient such as spondylosis deformans, reduced intervertebral disc spaces, malformation of vertebrae.¹³ The brachycephalic breeds, which

have “screw-tailed”, such as Pugs, French bulldogs, English Bulldogs, American Bully, Bull Terrier, and Boston Terrier, had a close relation with thoracic hemivertebra.^{14,15,16,17,18}

To complement this problem, heart-to-single vertebra ratio (HSVR) is suggested.¹¹ HSVR, which designed by Costanza, D, et al.(2023), is a novel method of Figure out the cardiac silhouette by using the grand total of the long and short axis of the cardiac and dividing by individual vertebral body length.¹¹ There is a study about the correlation verification between HSVR and VHS.¹¹ But, the study about the correlates with HSVR and VHS in screw tailed brachycephalic breeds was unknown.

Therefore, our primary objective was to investigate the correlation between HSVR and VHS at the screw-tailed brachycephalic breeds. Also, secondary aim was confirmation that HSVR can be a more effective method than VHS, at the way of measurement the cardiac silhouette volume.

Materials and Methods

1. Sample selection

This retrospective study was conducted by canine patients which was presented to Jeju National University and 3 local animal hospital during 2015-2023. Evaluated records were 94 dogs with Right lateral recumbency of thorax.¹² The breeds of dogs limited by screw-tailed brachycephalic breeds, such as Boston terrier, American bully, French bulldog, Bull Terrier, and Pug regardless of the cardiac disease. All of the patients had radiographic examination during the maximal inspiration.²⁵

Among the data, 23 patients which had difficulty measuring the vertebra length due to fusion of the multiple vertebral body, were excluded.

Out of 71 radiograph data, 22 images, the patient having vertebral deformans from the 4th thoracic vertebra to 8th thoracic vertebra, sorted by abnormal group. Consequently, radiographic images from 49 patients were sorted by normal group.

2. Image analysis

The age, sex, weight, breed and the date of the radiograph was recorded and documented in the electronic spreadsheet. Every radiograph image was analyzed by three veterinarians, who are on the ground students in the progress of radiology, with cross verification in DICOM format.²⁰ VHS technique, comparing the long axis (LA) which represents the length from carina to the apex of the cardiac, short axis (SA) which represents maximum perpendicular length of the LA, and vertebra body from the fourth thoracic vertebra, was used to the basis of the cardiac silhouette size.³ To measure the length of the cardiac silhouette and the vertebra body, three observers used the INFINITT PACS program (INFINITT Healthcare Co). All of the observers measured each length of the cardiac long axis (LA), the cardiac short axis (SA), the VHS, the fourth vertebral body (T4), the fifth (T5), the sixth (T6), the seventh (T7), and the eighth (T8), in right recumbent position image, at least 2 times. LA length was measured from the carina to the apex of the cardiac silhouette. SA length measured the maximum perpendicular length of LA. VHS technique, comparing the sum of LA and SA, with the vertebral body from the fourth thoracic vertebra, used to the basis of the cardiac silhouette size. Each length of the vertebral body included from the cranial end plate of the vertebra to the caudal intervertebral disc space (Figure 1).

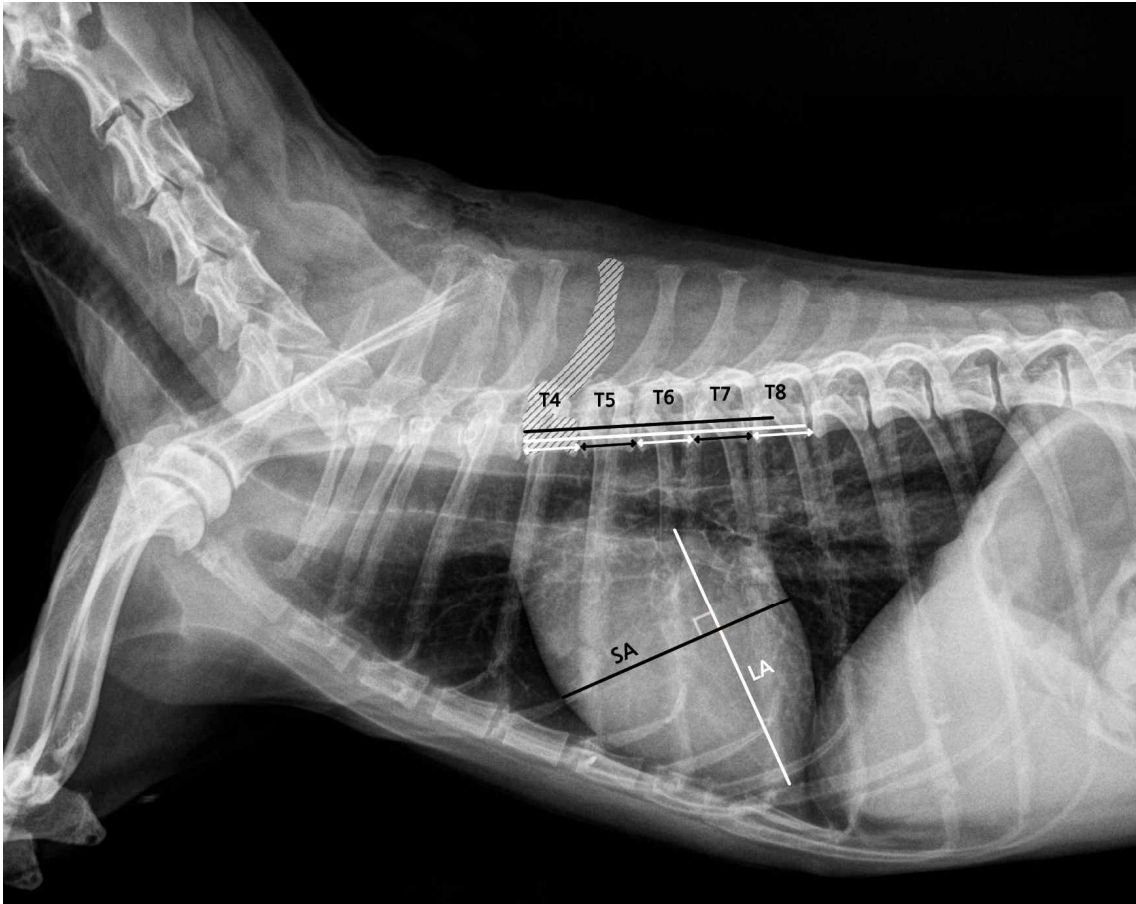

Figure 1. Delineate the method of vertebral heart score and Heart to Single Vertebral Ratio in right lateral recumbency of thoracic radiography image. LA represents long axis of heart outline. SA represents short axis of heart outline. Each of arrows show width of each T4-T8 vertebral body include intervertebral disc space.

3. Statistic analysis

The statistical analysis performed, using the statistical software (IBM SPSS statistics version 19, New York). The accordance rate for HSVR and VHS for 72 dogs estimated by Lin's concordance correlation coefficient (CCC) with correlating 95% Confidence Interval(CI). Agreement between two measurements rated by the cut-off values which suggested by Mc bride.²² Also, degree of agreement notated with Bland-Altman plots.²³ Intraclass correlation coefficients (ICC), suggested by Koo, and Li, used to verify the agreement between intra- and inter-observer.²¹ Statistical significance defined as $P < 0.05$ in analyses for all of the outcome.

Results

Among the 94 radiograph images, 71 images were included in the study and divided in two groups. There were 35 castrated males, 10 intact males, 17 spayed females, and 9 intact females. The mean age and mean body weight of two group showed 8.08 years (range 1-15 years) and 10.19kg (5.4-16.85kg).

1. Normal group

Normal group was arranged without any hemivertebra, oval, round, wedge-shaped, or kyphosis. This group included 49 dogs (26 castrated males, 7 intact males, 10 spayed females, and 6 intact females), Boston Terrier (n=21), Bull Terrier (n=1), American bully (n=2), Pug (n=13), and French Bulldog (n=12). The mean age was 5.0 years (range 1-13 years) and mean body weight was 10.1kg (range 5.4-16.85kg).

In normal group, Lin's CCC illustrate moderate agreement of 6th HSVR (0.936; 95% CI 0.916 to 0.951), 4th HSVR (0.932; 95% CI 0.910 to 0.948), 7th HSVR (0.923; 95% CI 0.897 to 0.943), 5th HSVR (0.909; 95% CI 0.878 to 0.933), and 8th HSVR (0.907; 95% CI 0.877 to 0.930) (Figure 2.A-E).

The mean of the Bland-Altman plots presents 0.062 for 6th HSVR (± 0.342 ; 95% CI -0.006 to -0.118), 0.074 for 7th HSVR (± 0.348 ; 95% CI -0.017 to -0.130), -0.127 for 4th HSVR (± 0.347 ; 95% CI -0.184 to -0.705), -0.084 for 5th HSVR (± 0.397 ; 95% CI -0.149 to -0.192), and 0.253 for 8th HSVR (± 0.338 ; 95% CI -0.198 to -0.308) (Figure 2. F-J).

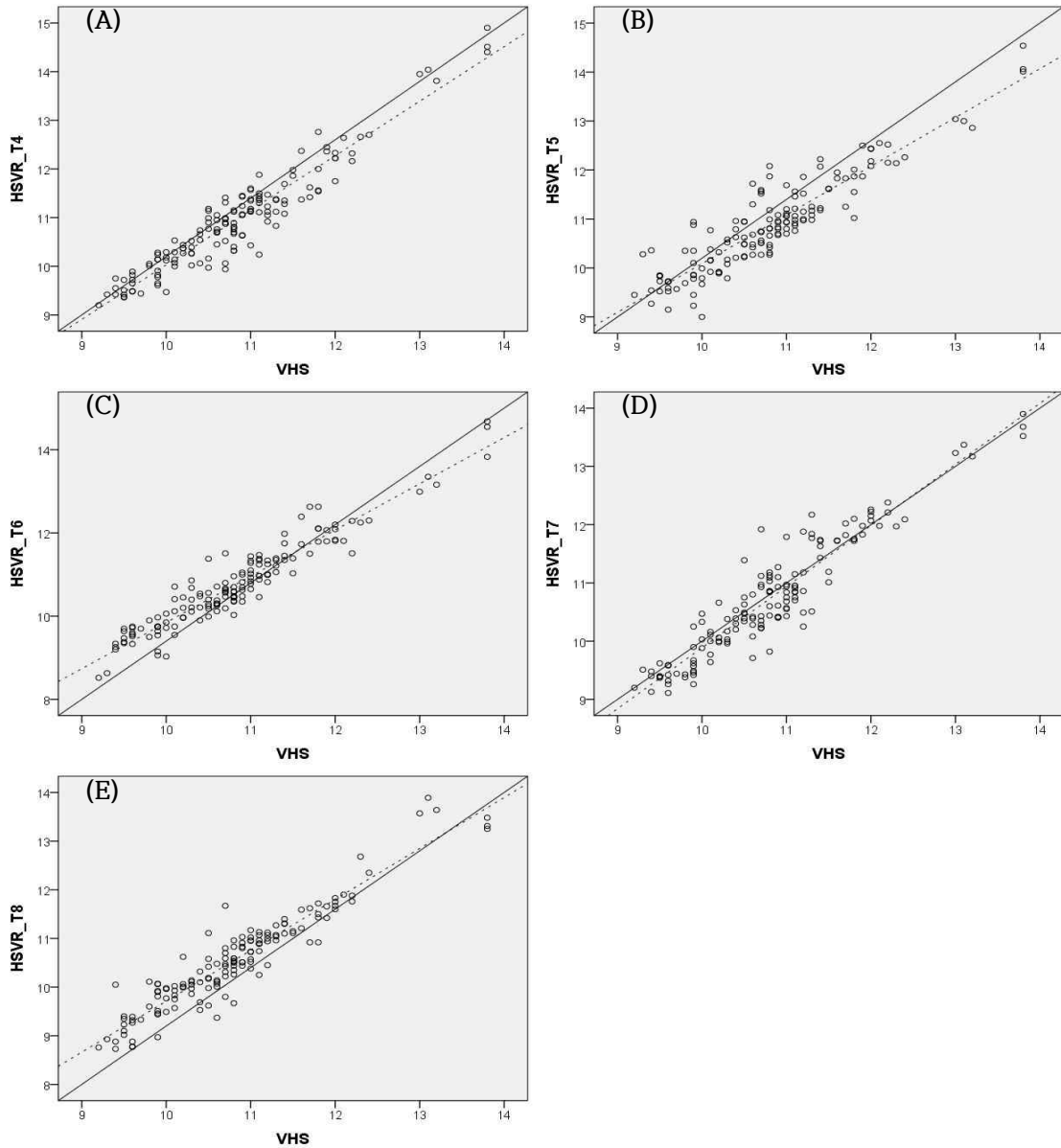


Figure 2. Graph of Lin' concordance correlation coefficient (CCC) and Bland-Altman plots at normal vertebral body group. In Lin's CCC graph, x-axis represent the vertebral heart score (VHS), and y-axis represents the Heart to Single Vertebral Ratio (HSVR). (continues)

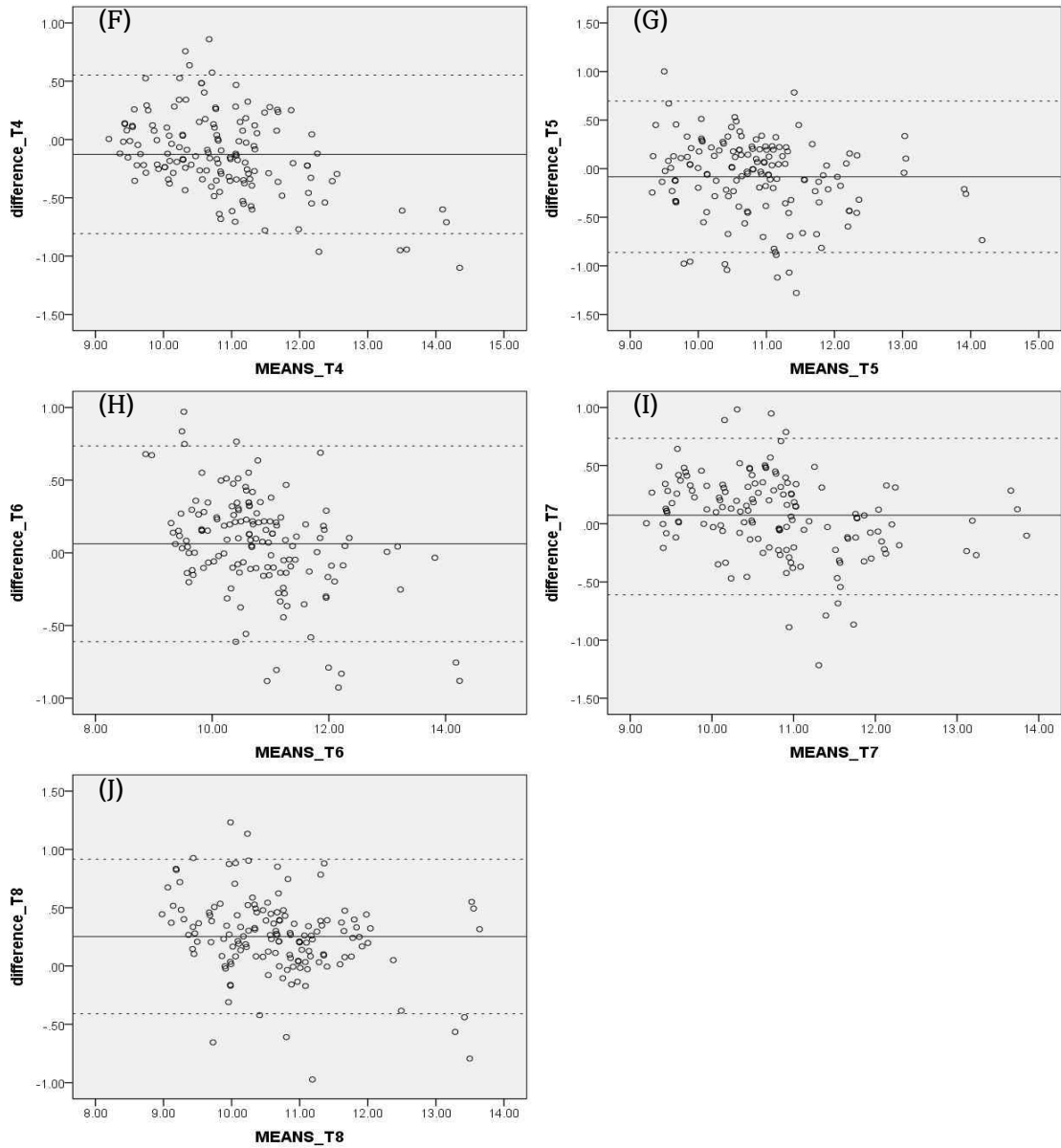


Figure 2. (continued) In Bland-Altman plots, each of HSVR from T4-T8 (F-J) compare with VHS. In the graph of Bland-Altman plots, x-axis demonstrates mean of VHS and HSVR. The y-axis demonstrates difference between VHS and HSVR.

2. Abnormal group

Abnormal group was arranged with thoracic vertebral shape deformation. Abnormal group involved 22 dogs (9 castrated males, 3 intact males, 7 spayed females, and 3 intact females, Boston Terrier (n=4), Bull Terrier (n=4), Pug (n=2), and French Bulldog (n=12). The mean age and mean weight of the secondary group was 5.8 years (range 1 to 15 years) and 10.38kg (range 5.4 to 15.4kg).

In abnormal group, Lin's CCC shows poor agreement of 7th HSVR (0.093; 95% CI -0.007 to 0.191), 4th HSVR (0.326; 95% CI 0.154 to 0.479), 6th HSVR (0.425; 95% CI 0.286 to 0.546), 8th HSVR (0.516; 95% CI 0.417 to 0.603), and 5th HSVR (0.518; 95% CI 0.335 to 0.664) (Figure 3.A-E).

The mean of the Bland-Altman plots presents 0.137 for 8th HSVR (± 2.426 ; 95% CI -0.460 to 0.733), -0.224 for 6th HSVR (± 2.435 ; 95% CI -0.822 to 0.375), 0.402 for 5th HSVR (± 1.427 ; 95% CI 0.051 to 0.752), 0.496 for 4th HSVR (± 2.339 ; 95% CI -0.787 to 1.072), and -2.311 for 7th HSVR (± 4.576 ; 95% CI -3.436 to -1.186) (Figure 3.F-J).

Also, the analysis of Lin's CCC between individual HSVR range in abnormal group demonstrates poor agreement, HSVR_T4-T5 (0.089; 95% CI -0.133 to 0.303), HSVR_T4-T6 (0.079; 95% CI -0.154 to 0.304), HSVR_T4-T7 (0.153; 95% CI -0.007 to 0.306), HSVR_T4-T8 (0.295; 95% CI 0.068 to 0.493), HSVR_T5-T6 (0.346; 95% CI 0.162 to 0.508), HSVR_T5-T7 (-0.026; 95% CI -0.144 to 0.092), HSVR_T5-T8 (0.557; 95% CI 0.426 to 0.665), HSVR_T6-T7 (-0.241; 95% CI -0.415 to -0.051), HSVR_T6-T8 (0.567; 95% CI 0.381 to 0.79), and HSVR_T7-T8 (-0.083; 95% CI -0.270 to 0.110) (Figure 4).

Both of ICC about inter-observer agreement and intra-observer agreement prove that all measurement have excellent agreement (Table 1; $p=0.000$, Table 2; $p<0.001$).

At abnormal group, vertebral malformation commonly involved on T8 (n=15), T7 (n=11), T6 (n=7), T5 (n=5), and T4 (n=1) (Figure 5).

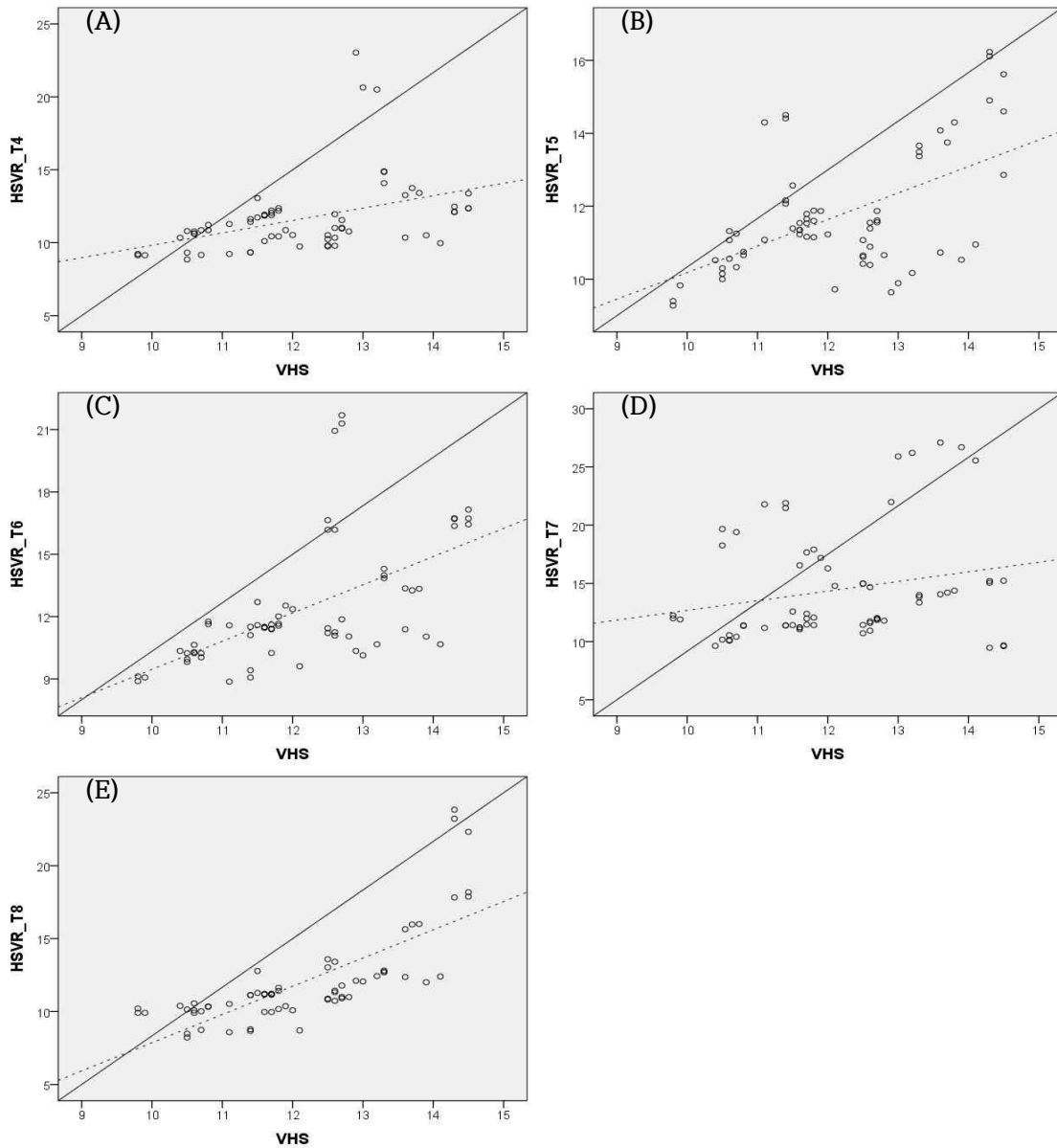


Figure 3. Graph of concordance correlation coefficient (CCC) and Bland-Altman plots at abnormal group. In Lin's CCC graph, x-axis represent the vertebral heart score (VHS), and y-axis represents the Heart to Single Vertebral Ratio (HSVR). (continues)

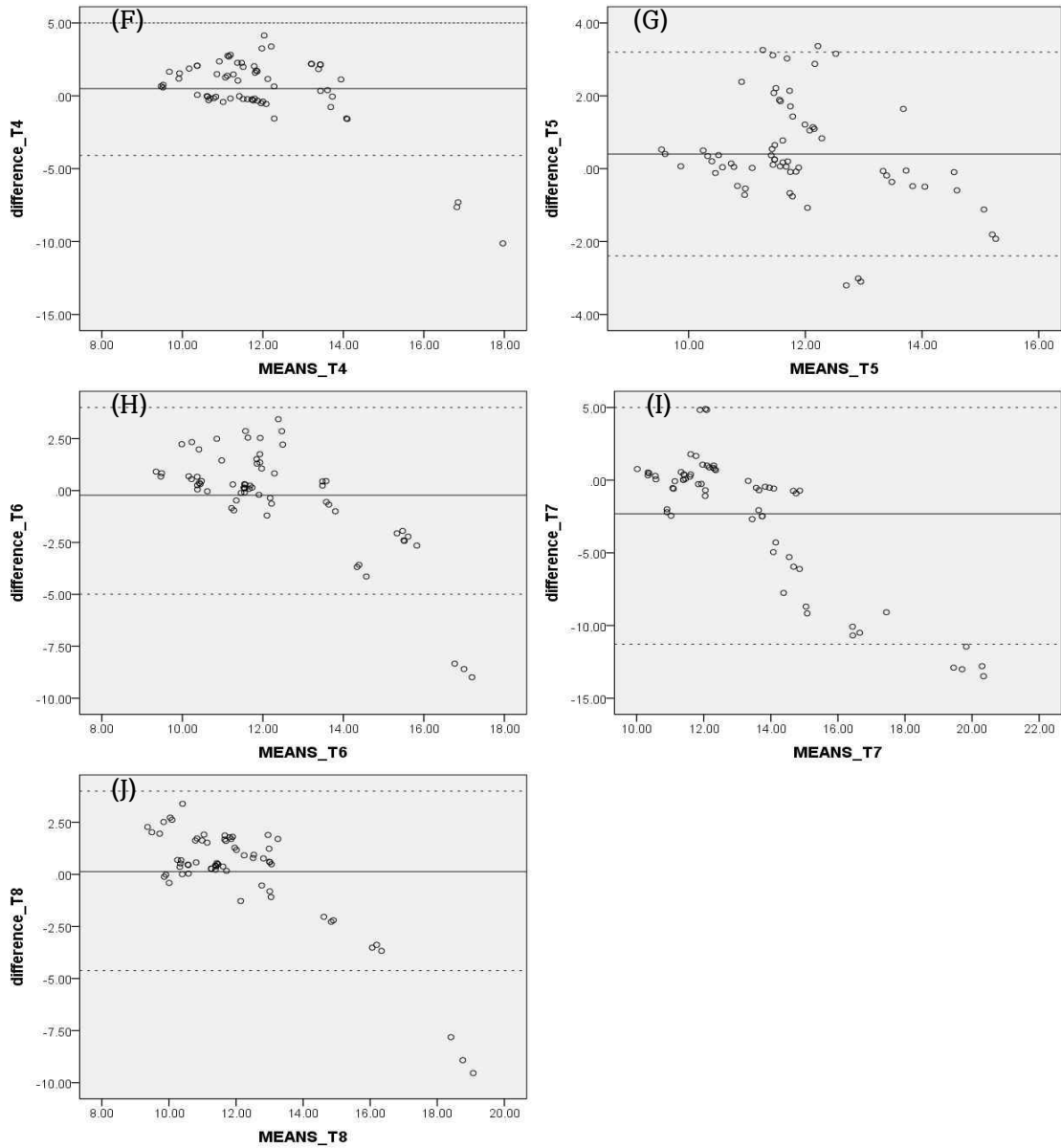


Figure 3. (continued) In Bland-Altman plots, each of HSVR from T4-T8 (F-J) compare with VHS. In the graph of Bland-Altman plots, x-axis demonstrates mean of VHS and HSVR. The y-axis demonstrates difference between VHS and HSVR.

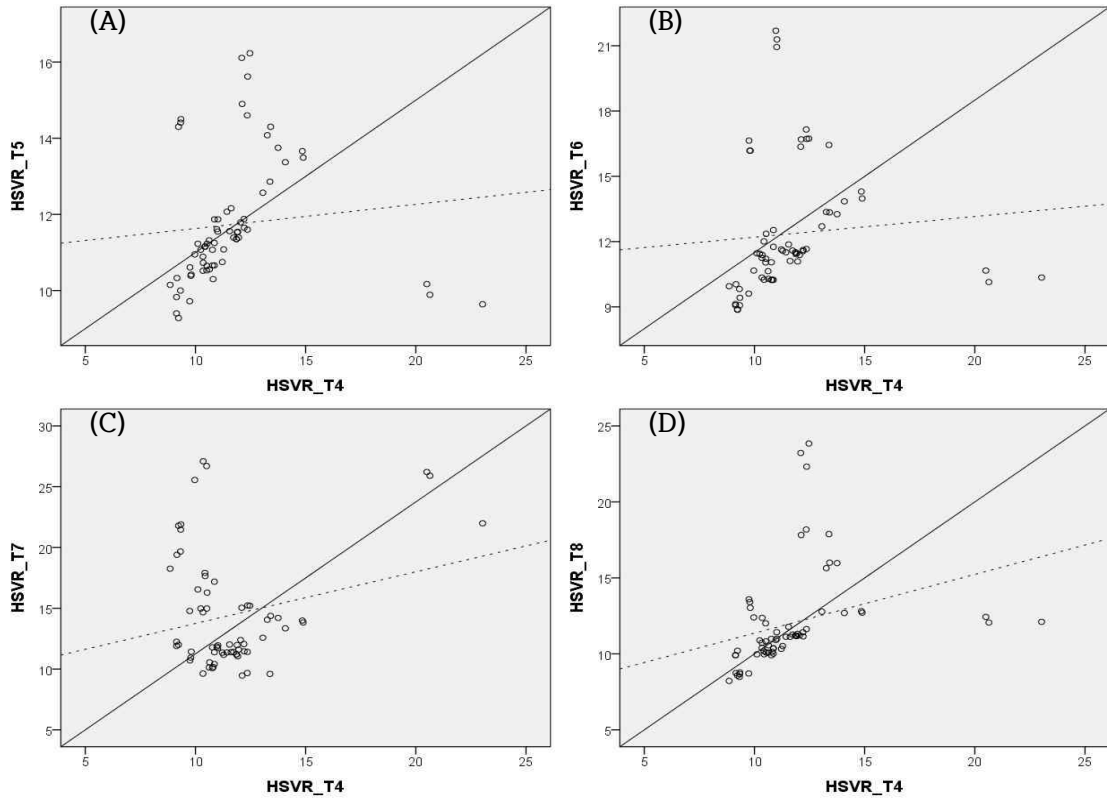


Figure 4. Graph of Lin's concordance correlation coefficient (CCC) at abnormal group. Each of Heart to Single Vertebral Ratio (HSVR) compare by another HSVR. (continues)

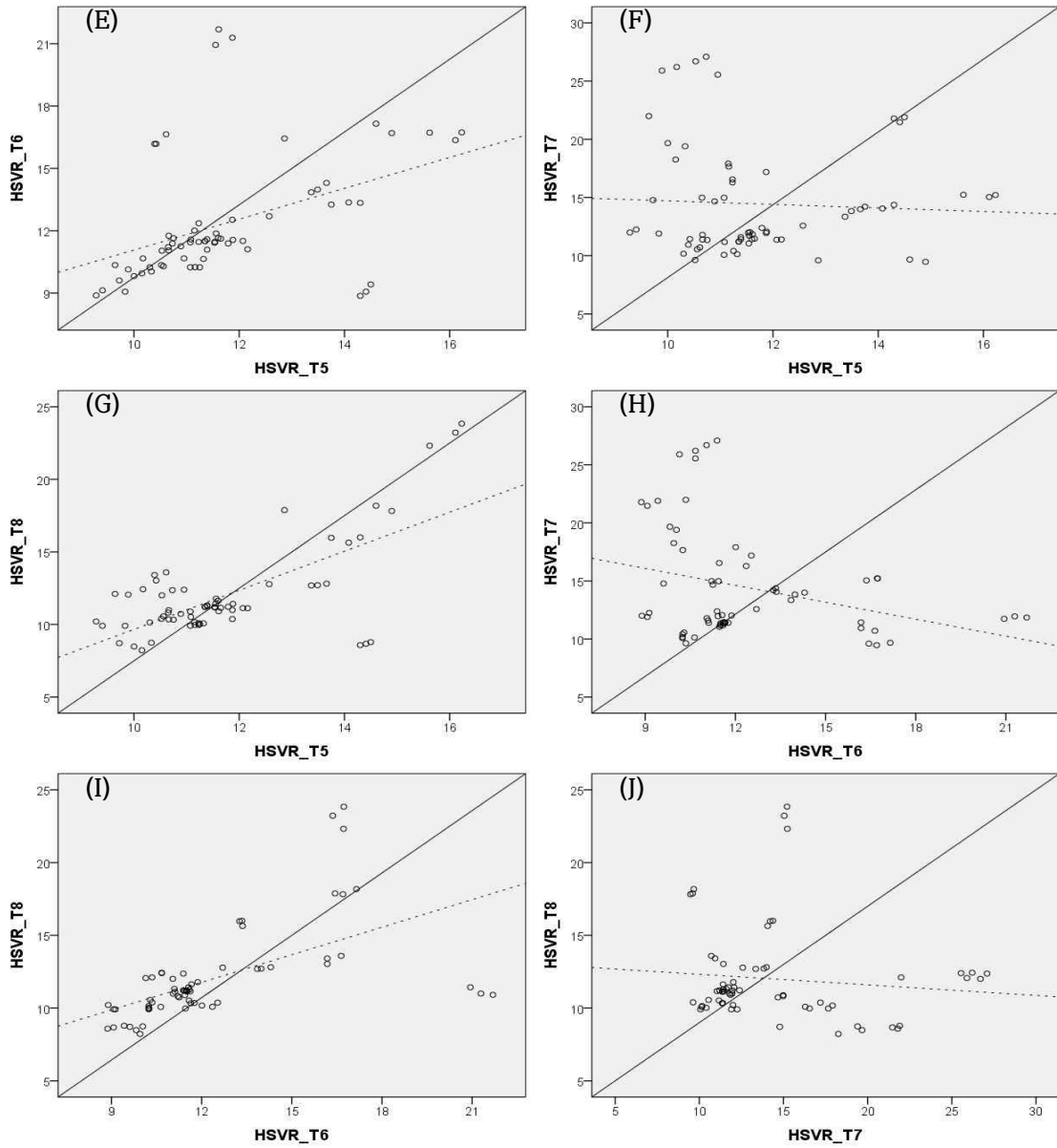


Figure 4. (continued) Graph of Lin's concordance correlation coefficient (CCC) at abnormal group. Each of H_SVR compare by another H_SVR.

Table 1. Inter-observer agreement at Intraclass correlation coefficient among three observers.

	ICC (n=71)	95% CI
VHS	0.994	0.992-0.996
T ⁴ HSVR	0.989	0.984-0.993
T ⁵ HSVR	0.979	0.969-0.986
T ⁶ HSVR	0.99	0.986-0.994
T ⁷ HSVR	0.995	0.992-0.997
T ⁸ HSVR	0.995	0.993-0.997

Table 2. Intra-observer agreement at Intraclass correlation coefficient among three observers

	ICC (95%CI) (n=20)		
	Observer 1	Observer 2	Observer 3
VHS	0.998 (0.995-0.999)	0.999 (0.997-1)	0.991 (0.979-0.997)
T ⁴ HSVR	0.994 (0.985-0.998)	0.901 (0.752-0.960)	0.988 (0.971-0.995)
T ⁵ HSVR	0.996 (0.991-0.999)	0.910 (0.775-0.964)	0.976 (0.939-0.991)
T ⁶ HSVR	0.997 (0.993-0.999)	0.850 (0.662-0.941)	0.984 (0.960-994)
T ⁷ HSVR	0.992 (0.980-0.997)	0.916 (0.782-0.967)	0.970 (0.925-0.988)
T ⁸ HSVR	0.998 (0.995-0.999)	0.937 (0.841-0.975)	0.987 (0.967-0.995)

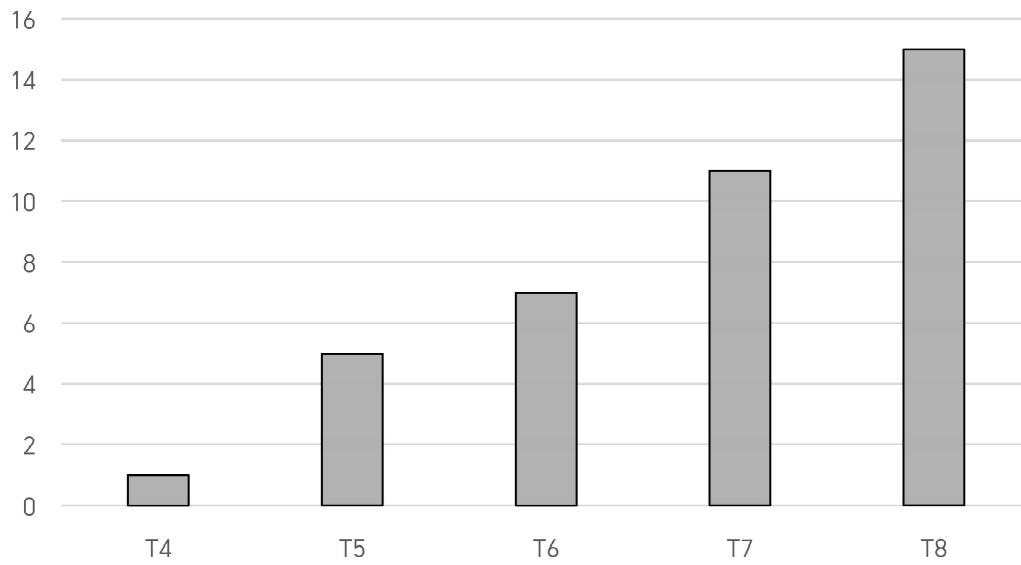


Figure 5. Vertebral malformation distribution chart on abnormal group. The x-axis represents each thoracic vertebral body. The y-axis represents the number of malformation vertebral body.

Discussion

HSVR is new method calculating the cardiac silhouette by using the individual vertebral body length. This method designed by Costanza. et al in 2023.¹² In the former study demonstrated substantial agreement of 7th HSVR (0.983;95% CI 0.974 to 0.989), 8th HSVR (0.964; 95% CI 0.946 to 0.977), 6th HSVR (0.96; 95% CI 0.94 to 0.973), and 5th HSVR (0.958; 95% CI 0.936 to 0.972) with VHS, and moderate agreement of 4th HSVR (0.938; 95% CI 0.90 to 0.95) with VHS.¹² By this result, former study expected that there is a reliability with VHS and HSVR.¹² Also, the former study anticipate that HSVR is better method than VHS in screw-tailed brachycephalic breed, which have congenital vertebral formation. In this study, 94 patients were analyzed. Among the data, 23 patients were excluded, which have fusion between vertebral body. The 71 patients were sorted two groups. In normal group consists of the dogs without hemivertebra deformans. On the other hand, in abnormal group contained the dogs with thoracic vertebral abnormalities. In agreement with findings of the former study, our results proposed that there is a reliability in HSVR with VHS in the normal group.

All of the HSVR shows moderate agreement with VHS on Lin's CCC analysis. It follows 0.936 for 6th HSVR, 0.932 for 4th HSVR, 0.923 for 7th HSV, 0.909 for 5th HSVR, and 0.907 for 8th HSVR. The moderate agreement between VHS and HSVR associate with agreement between each HSVR. Due to this reason, Lin'ccc between each HSVR doesn't included on this study. The mean difference shows under 0.4. In agreement with findings of the former study, our results proposed that there is a reliability in HSVR with VHS in the normal group. By this result, HSVR expects as the method that could alternate the VHS.

The previous study suggested HSVR for the new method of calculating

cardiac silhouette with the patients who have congenital alteration on their thoracic vertebra.¹¹ Though in abnormal group, our study demonstrates poor reliability of both HSVR with VHS and each HSVR on Lin's CCC analysis. It follows 0.093 for 7th HSVR, 0.326 for 4th HSVR, 0.425 for 6th HSVR, 0.516 for 8th HSVR, and 0.518 for 5th HSVR. The mean difference shows over 2.0. Also the agreement between each HSVR in abnormal group represents poor agreement on Lin's CCC analysis. It follows 0.089 between 4th HSVR and 5th HSVR, 0.079 between 4th HSVR and 6th HSVR, 0.153 between 4th HSVR and 7th HSVR, 0.295 between 4th HSVR and 8th HSVR, 0.346 between 5th HSVR and 6th HSVR, -0.026 between 5th HSVR and 7th HSVR, 0.557 between 5th HSVR and 8th HSVR, -0.241 between 6th HSVR and 7th HSVR, 0.567 between 6th HSVR and 8th HSVR, and -0.083 between 7th HSVR and 8th HSVR. By this result, our study confirms that HSVR is hard to be the method to alternate the VHS in the patient with thoracic vertebral deformans.

The reason for these results is considered to be the impact of factors such as the shortening of the length even in vertebral bodies with a normal shape when there are congenital thoracic vertebral abnormalities.¹⁹ Therefore, even when scoring the heart size using the single vertebra body length that appears normal, if scoring is done using body length that appears normal but belongs to a different normal vertebra, the probability of obtaining different values is high. Therefore, the reliability of HSVR is considered to decrease in patients with congenital vertebral malformations.

Decker. S et al. reported that thoracic vertebral malformation mostly occurred in the order of on T8, T7, T6, T4 and T5.¹⁷ In our study, thoracic vertebral malformation mostly involved in T8 (n=15), T7 (n=11), T6 (n=7), T5 (n=5), and T4 (n=1). This result is similar to previous study about thoracic hemivertebra in screw tailed brachycephalic breed.¹⁷

In this study has certain limitations. First of all, our sample number was

insufficient in abnormal group.²⁴ Secondly, experience of observers showed high relationship between results. In past experiments also verified the connection between the observer's experience and determining a line of demarcation.^{6,7,8,9}

In further studies, if there is bigger sample and higher experienced observer to study about a new technique to evaluate the cardiac silhouette for the dogs who have congenital thoracic vertebral deformans, would be useful.

In this study, we find the correlation between HSVR and VHS at the screw-tailed brachycephalic breeds. The HSVR can be alternative method of VHS in normal group, which doesn't have any thoracic vertebral abnormalities. Though, HSVR cannot produce a better result than VHS method in congenital thoracic vertebral abnormalities in screw-tail brachycephalic breeds.

Conclusion

VHS has limitation with congenital thoracic vertebral disease patient. The purpose of this study is verifying the correlation between HSVR and VHS, and the possibility that HSVR can replace VHS in screw-tailed brachiocephalic breeds. The agreement between HSVR and VHS is calculated with Lin's CCC and Bland-Altman plots. As a result, the agreement between HSVR and VHS in normal group represents moderate degree. But, the agreement between HSVR and VHS and coincidence ratio between each HSVR in abnormal group represents poor degree. By this result, our study reach a conclusion that HSVR can used in screw tailed brachycephalic breed with out vertebral abnormality. Though, HSVR cannot be the alternation method at vertebral abnormality patient in screw tailed brachycephalic breeds.

References

1. Brambilla PG, Polli M, Pradelli D, et al. Epidemiological study of congenital heart diseases in dogs: Prevalence, popularity, and volatility throughout twenty years of clinical practice. *PLoS One*. 2020;15(7):e0230160. Published 2020 Jul 27.
2. Buchanan JW, Bücheler J. Vertebral scale system to measure canine heart size in radiographs. *J Am Vet Med Assoc*. 1995;206(2):194-199.
3. Lamb CR, Tyler M, Boswood A, Skelly BJ, Cain M. Assessment of the value of the vertebral heart scale in the radiographic diagnosis of cardiac disease in dogs. *Vet Rec*. 2000;146(24):687-690.
4. Lamb CR, Wikeley H, Boswood A, Pfeiffer DU. Use of breed-specific ranges for the vertebral heart scale as an aid to the radiographic diagnosis of cardiac disease in dogs. *Vet Rec*. 2001;148(23):707-711.
5. Lord P, Hansson K, Kvart C, Häggström J. Rate of change of heart size before congestive heart failure in dogs with mitral regurgitation. *J Small Anim Pract*. 2010;51(4):210-218.
6. Kraetschmer S, Ludwig K, Meneses F, Nolte I, Simon D. Vertebral heart scale in the beagle dog. *J Small Anim Pract*. 2008;49(5):240-243.
7. Bavegems V, Van Caelenberg A, Duchateau L, Sys SU, Van Bree H, De Rick A. Vertebral heart size ranges specific for whippets. *Vet Radiol Ultrasound*. 2005;46(5):400-403.
8. Marin LM, Brown J, McBrien C, Baumwart R, Samii VF, Couto CG. Vertebral heart size in retired racing Greyhounds. *Vet Radiol Ultrasound*. 2007;48(4):332-334.
9. Luciani MG, Withoef JA, Mondardo Cardoso Pissetti H, et al. Vertebral heart size in healthy Australian cattle dog. *Anat Histol Embryol*. 2019;48(3):264-267.
10. Marbella Fernández D, García V, Santana AJ, Montoya-Alonso JA. The Thoracic Inlet Length as a Reference Point to Radiographically Assess Cardiac Enlargement in Dogs with Myxomatous Mitral Valve Disease. *Animals (Basel)*. 2023;13(16):2666. Published 2023 Aug 18.
11. Costanza D, Greco A, Piantedosi D, et al. The heart to single vertebra ratio: A

- new objective method for radiographic assessment of cardiac silhouette size in dogs. *Vet Radiol Ultrasound*. 2023;64(3):378-384.
12. Greco A, Meomartino L, Raiano V, Fatone G, Brunetti A. Effect of left vs. right recumbency on the vertebral heart score in normal dogs. *Vet Radiol Ultrasound*. 2008;49(5):454-455.
 13. Jepsen-Grant K, Pollard RE, Johnson LR. Vertebral heart scores in eight dog breeds. *Vet Radiol Ultrasound*. 2013;54(1):3-8.
 14. Bailey CS, Morgan JP. Congenital spinal malformations. *Vet Clin North Am Small Anim Pract*. 1992;22(4):985-1015.
 15. Mansour TA, Lucot K, Konopelski SE, et al. Whole genome variant association across 100 dogs identifies a frame shift mutation in DISHEVELLED 2 which contributes to Robinow-like syndrome in Bulldogs and related screw tail dog breeds. *PLoS Genet*. 2018;14(12):e1007850. Published 2018 Dec 6.
 16. Besalti O, Ozak A, Pekcan Z, Eminaga S. Nasca classification of hemivertebra in five dogs. *Ir Vet J*. 2005;58(12):688-690. Published 2005 Dec 1.
 17. De Decker S, Packer RMA, Cappello R, et al. Comparison of signalment and computed tomography findings in French Bulldogs, Pugs, and English Bulldogs with and without clinical signs associated with thoracic hemivertebra. *J Vet Intern Med*. 2019;33(5):2151-2159.
 18. Ryan R, Gutierrez-Quintana R, Ter Haar G, De Decker S. Prevalence of thoracic vertebral malformations in French bulldogs, Pugs and English bulldogs with and without associated neurological deficits. *Vet J*. 2017;221:25-29.
 19. Gutierrez-Quintana R, Guevar J, Stalin C, Faller K, Yeamans C, Penderis J. A proposed radiographic classification scheme for congenital thoracic vertebral malformations in brachycephalic "screw-tailed" dog breeds. *Vet Radiol Ultrasound*. 2014;55(6):585-591.
 20. Sánchez X, Prandi D, Badiella L, et al. A new method of computing the vertebral heart scale by means of direct standardisation. *J Small Anim Pract*. 2012;53(11):641-645.
 21. Koo TK, Li MY. A Guideline of Selecting and Reporting Intraclass Correlation Coefficients for Reliability Research [published correction appears in *J Chiropr*

- Med. 2017 Dec;16(4):346]. J Chiropr Med. 2016;15(2):155-163.
22. McBride GB. A proposal for strength-of-agreement criteria for Lin's Concordance Correlation Coefficient. 2005 NIWA Client Report: HAM2005-062. 2005;45:307-310.
 23. Bland JM, Altman DG. Measuring agreement in method comparison studies. Stat Methods Med Res. 1999;8(2):135-160.
 24. Friedrichs KR, Harr KE, Freeman KP, et al. ASVCP reference interval guidelines: determination of de novo reference intervals in veterinary species and other related topics. Vet Clin Pathol. 2012;41(4):441-453.
 25. Olive J, Javard R, Specchi S, et al. Effect of cardiac and respiratory cycles on vertebral heart score measured on fluoroscopic images of healthy dogs. J Am Vet Med Assoc. 2015;246(10):1091-1097.