



저작자표시-비영리-변경금지 2.0 대한민국

이용자는 아래의 조건을 따르는 경우에 한하여 자유롭게

- 이 저작물을 복제, 배포, 전송, 전시, 공연 및 방송할 수 있습니다.

다음과 같은 조건을 따라야 합니다:



저작자표시. 귀하는 원저작자를 표시하여야 합니다.



비영리. 귀하는 이 저작물을 영리 목적으로 이용할 수 없습니다.



변경금지. 귀하는 이 저작물을 개작, 변형 또는 가공할 수 없습니다.

- 귀하는, 이 저작물의 재이용이나 배포의 경우, 이 저작물에 적용된 이용허락조건을 명확하게 나타내어야 합니다.
- 저작권자로부터 별도의 허가를 받으면 이러한 조건들은 적용되지 않습니다.

저작권법에 따른 이용자의 권리는 위의 내용에 의하여 영향을 받지 않습니다.

이것은 [이용허락규약\(Legal Code\)](#)을 이해하기 쉽게 요약한 것입니다.

[Disclaimer](#)

Thesis for the degree of Master of Veterinary Medicine

Intestinal Stenosis after Chemotherapy
in a Cat with High-Grade Alimentary
Lymphoma

Hyun Jeong Hong

Department of Veterinary Medicine

The Graduate School

Jeju National University

February 2024

Intestinal Stenosis after Chemotherapy in a Cat with High-Grade Alimentary Lymphoma

A Thesis submitted to the graduate school of
Jeju National University in partial fulfillment of
the requirements for the degree of Master of veterinary medicine
under the supervision of **Woo-Jin Song**

A thesis for the degree of Master of Veterinary Medicine
by **Hyun Jeong Hong**
has been approved by the dissertation committee.

December 2023

Chair	Yun, YoungMin	_____
Member	Kim, Myung-Chul	_____
Member	Song, Woo-Jin	_____

Contents

I. Introduction	1
II. Materials and Methods	2
III. Results	4
IV. Discussion	12
V. Conclusion	14
VI. References	15
국문 초록	17

Intestinal Stenosis after Chemotherapy in a Cat with High-Grade Alimentary Lymphoma

Hyun Jeong Hong

Department of Veterinary Medicine
The Graduate School
Jeju National University

Abstract

A 3-year-old, castrated male, domestic short-hair cat was presented to the Western Referral Animal Medical Center (Seoul, Korea) with lethargy, anorexia, and melena of two days of duration. Abdominal ultrasonography revealed that the small intestinal mass (6 × 3.5 cm) was hypoechoic and had disrupted normal wall layering. High-grade alimentary lymphoma was diagnosed based on fine-needle aspiration cytology. During cyclophosphamide, doxorubicin, vincristine and prednisolone (CHOP)-based chemotherapy, the patient was admitted to emergency care because of vomiting and depression. Abdominal ultrasonography revealed an intestinal stenosis at the lymphoma site. The patient underwent surgery to resolve the mechanical ileus. The remains in complete remission at the time of this report. To the best of our knowledge, this is the first reported case of an intestinal stenosis that might be occurred after CHOP-based chemotherapy for high-grade alimentary lymphoma.

Keywords: Alimentary lymphoma, Chemotherapy, Intestinal Stenosis, Feline

I. Introduction

Alimentary lymphoma is the most common form of lymphoma and is frequently diagnosed in cats [2, 8, 12]. Feline alimentary lymphoma can be classified into three types based on histopathology and immunohistopathology, namely (1) low-grade alimentary lymphoma, (2) intermediated- or high-grade alimentary lymphoma (I/HGAL), and (3) large granular lymphoma. In case with I/HGAL, an aggressive combination chemotherapy is considered for treatment [3]. While administering multidrug chemotherapy, such as cyclophosphamide, vincristine, prednisolone (COP)- or cyclophosphamide, doxorubicin, vincristine, and prednisolone (CHOP)-based protocols, low-grade hematologic and gastrointestinal toxicosis are common [6, 10].

While treating feline I/HGAL with a chemotherapy-first approach, surgical emergencies are restricted to intestinal obstruction due to poor response or intestinal perforation with peritonitis [3]. However, in humans, there are several cases of intestinal stricture, also requiring surgical intervention, after intestinal lymphoma with a complete response to chemotherapy [5, 7].

There is a study regarding ultrasonographic features with feline intestinal fibrotic stricture [4]. As abdominal ultrasonography can easily employed in veterinary practice, feline intestinal stricture following chemotherapy could be diagnosed without using computed tomography.

Herein, we present a first case report of intestinal stenosis following CHOP-based chemotherapy in a feline high-grade alimentary lymphoma. A feline patient in this case underwent ileocolic anastomosis due to mechanical obstruction.

II. Materials and Methods

1. Clinical history of the feline patient

A 3-year-old, 4.67 kg, castrated male, domestic short-hair cat was presented to the Western Referral Animal Medical Center (Seoul, Korea) with lethargy, anorexia, and melena of two days duration. Physical examination the patient was depressed with pale mucous membranes, tachycardia, tachypnea and a palpable abdominal mass.

2. Laboratory examination

Complete blood count (CBC) was evaluated using the ADVIA2120i analyzer (Siemens, USA). Serum chemistry was performed using the HITACHI7020 (HITACHI, Japan). Blood typing was performed using a Feline A/B typing Qtest kit (Celltrix, Korea).

3. Imaging examination

Abdominal ultrasonography was performed using the Aplio 400 ultrasound machine (Canon medical systems corporation, Tokyo, Japan).

4. Cytologic examination

Fine-needle aspiration samples are stained using Diff quick stain.

5. Pathologic examination

Excisional biopsy samples stained with hematoxylin and eosin at the laboratory of Veterinary Pathology in IDEXX (USA).

6. Polymerase chain reaction for Antigen Receptor Rearrangements (PARR)

PARR assay performed at the laboratory of Pobanilab (Guri, Republic of

Korea).

7. CHOP-based protocol for the patient in this case

Week 1	Vincristine 0.5 mg/m ² IV, Prednisolone 2mg/kg PO q24hr
Week 2	Cyclophosphamide 200mg/m ² PO, Prednisolone 2mg/kg PO q24hr
Week 3	Vincristine 0.6 mg/m ² IV, Prednisolone 1mg/kg PO q24hr
Week 6	Doxorubicin 25mg/m ² IV, Prednisolone 1mg/kg PO q48hr
Week 8	Vincristine 0.6 mg/m ² IV, Prednisolone 1mg/kg PO q48hr
Week 9	Cyclophosphamide 200mg/m ² PO, Prednisolone 1mg/kg PO q48hr
Week 10	Vincristine 0.6 mg/m ² IV, Prednisolone 1mg/kg PO q48hr
Week 11	Doxorubicin 25mg/m ² IV, Prednisolone 1mg/kg PO q48hr
Week 13	Vincristine 0.6 mg/m ² IV, Prednisolone 1mg/kg PO q48hr
Week 15	Cyclophosphamide 200mg/m ² PO, Prednisolone 1mg/kg PO q48hr
Week 17	Vincristine 0.6 mg/m ² IV, Prednisolone 1mg/kg PO q48hr
Week 19	Doxorubicin 25mg/m ² IV, Prednisolone 1mg/kg PO q48hr
Week 21	Vincristine 0.6 mg/m ² IV, Prednisolone 1mg/kg PO q48hr
Week 23	Cyclophosphamide 200mg/m ² PO, Prednisolone 1mg/kg PO q48hr
Week 25	Vincristine 0.6 mg/m ² IV, Prednisolone 1mg/kg PO q48hr
Week 27	Doxorubicin 25mg/m ² IV, Prednisolone 1mg/kg PO q48hr

IV, intravenous; PO, per oral (by mouth)

III. Results

The biochemical profile of this patient showed increased in ALP (139 U/L) and total bilirubin (0.23 mg/dl) (Table 1). As the patient is anorectic for two days and these abnormalities improved during hospitalization, hepatic lipidosis is considered rather than hemolytic anemia. The CBC results revealed regenerative anaemia (hematocrit [HCT]= 11.8%, reference interval(RI), 27.7-46.8% and reticulocyte count [RETIC#]= 131.5 K/ μ L, RI, 15.0-81.0 K/ μ L). Abdominal radiography revealed a large, round, soft tissue opaque mass in the center of the abdomen. Abdominal ultrasonography revealed a hypoechoic small intestinal mass (6 × 3.5 cm) with disrupted normal wall layering. Ultrasound-guided fine-needle aspiration of the abdominal mass revealed high cellularity with medium-to-large lymphocytes. High-grade alimentary lymphoma (HGAL) was diagnosed based on the cytology (Figure 1). A PARR assay performed using the cells aspirated from the intestinal mass revealed monoclonality of T-cell lineage. Feline immunodeficiency virus antibody and feline leukaemia virus antigen tests were negative. No other lymph node enlargements were detected on physical examination or thoracic radiography.

Table 1. Results of serum chemistry analysis of this patient

	Reference	Result		Unit
		Day 1	Day 2	
ALT/GPT	28 - 106	34		g/dl
ALP	9 - 53	139	82	U/L
Total protein	6.6 - 8.4	6.7		g/dl
Albumin	1.9 - 3.9	3.0		g/dl
Total bilirubin	0.0 - 0.2	0.23	0.18	mg/dl
Phosphorous	3.2 - 6.3	5.0		mg/dl

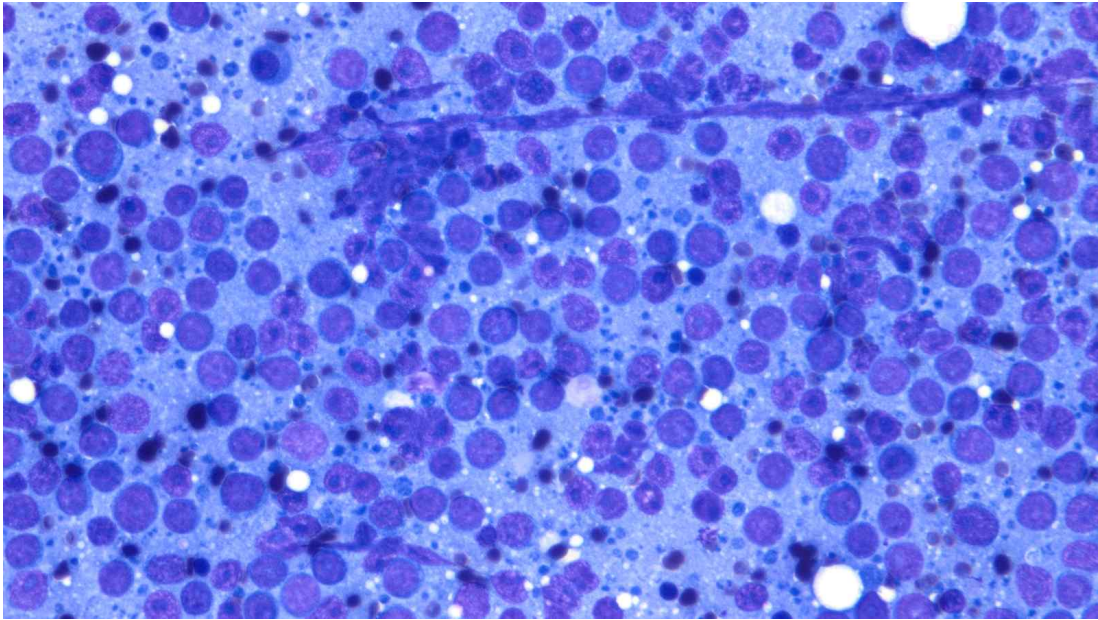


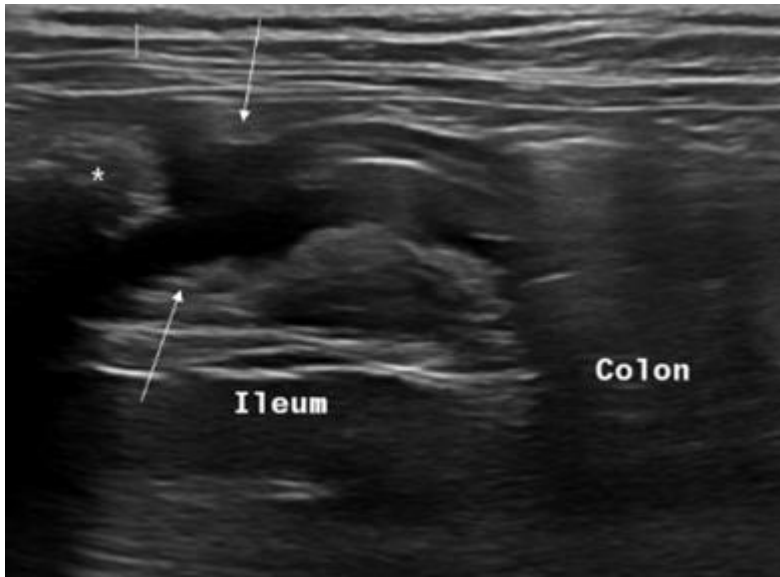Figure 1. Fine-needle aspiration sample from the intestinal mass of this patient. Immature and large lymphocytes are predominant. These cells have more abundant cytoplasm, pale chromatin, and one or more nucleoli.

As the patient experienced melena during hospitalization, intestinal haemorrhage was considered the cause of regenerative anaemia. In-house blood typing was performed and the patient was classified as Type A and 40ml of packed red blood cells, which was the only blood available at that time, was transfused. Other treatments included nasogastric tube feeding, oxygen supplementation, and intravenous administration of 0.9% normal saline. In addition, antibiotics including cefotaxime (Pharmgen Cefotaxime Sodium Inj.: 30 mg/kg, twice a day, intravenous; Pharmgenscience Pharmaceutical, Korea) and metronidazole (Metrinal Inj.: 15 mg/kg, twice a day, intravenous; Daihan Pharmaceutical, Korea) to prevent bacterial translocation. Mucosal protectants including famotidine (Gaster Inj.: 0.5 mg/kg, twice a day, intravenous; Donga-st Pharmaceutical, Korea) and sodium alginate (Algid solution: 100 mg/cat, twice a day, per os; SCD Pharmaceutical, Korea) to manage gastrointestinal haemorrhage, Maropitant (Cerenia: 1 mg/kg, once a day, per os; Zoetis, US) for nausea, and Ferric Hydroxide Polymaltose complex (Ferromax solution: 200 mg/cat, once a day, per os; Hanmi Pharmaceutical, Korea) for anemia were also provided.

The patient was treated using a CHOP-based chemotherapy protocol. Following the first vincristine dose (Vincran: 0.6 mg/m²; REYON Pharmaceutical, Korea; 1st week), the melena was improved and HCT increased from 14.9% to 23.9%. Five days after the first cyclophosphamide dose (Alkyloxan: 200mg/m², per os; JW Pharmaceutical, Korea; 2nd week), the patient presented with vomiting. Maropitant prescribed until next visit to prevent further vomiting. The second Vincristine dose (3rd week) was infused intravenously as scheduled. Two days later, the patient was admitted to emergency care department because of vomiting and depression. The intestinal mass had decreased in size (2.4 × 0.7cm), as observed using abdominal ultrasonography, suggesting that the patient had partial remission of HGAL. Segmental intestinal dilation with a kink at the original site of lymphoma (Figure 2) was observed and was considered nondilatable, namely, intestinal stenosis [3, 4]. Surgical intervention was performed.

Approximately 2 cm of either side of the lesion was resected during ileocecelectomy and an end-to-end anastomosis was performed. Although the patient developed a fever during the first three postoperative days, the patient was discharged from our hospital on the 6th day of hospitalization without any gastrointestinal complications. Histopathological examination of the resected ileocecal junction revealed mural ulceration with transmural inflammatory infiltrates (Figure 3). Though PARR had not performed, atypical lymphocytes were not observed in the resected tissue section.

A



B

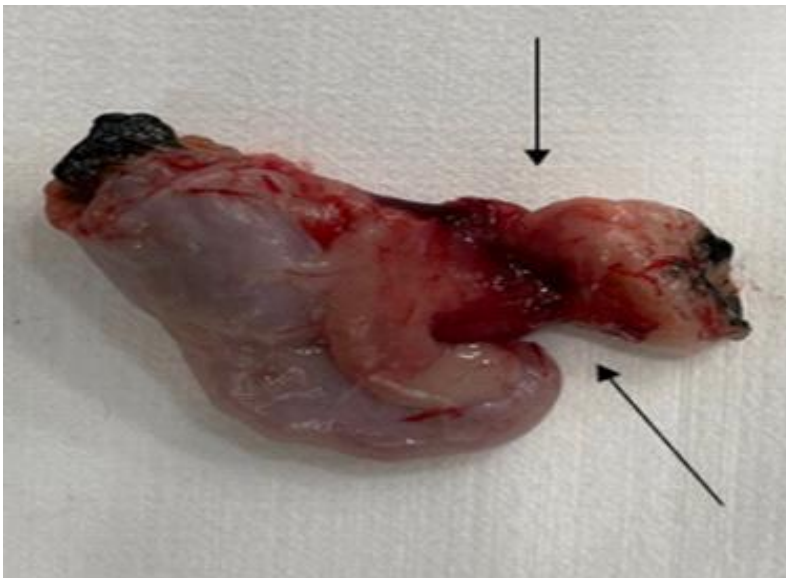
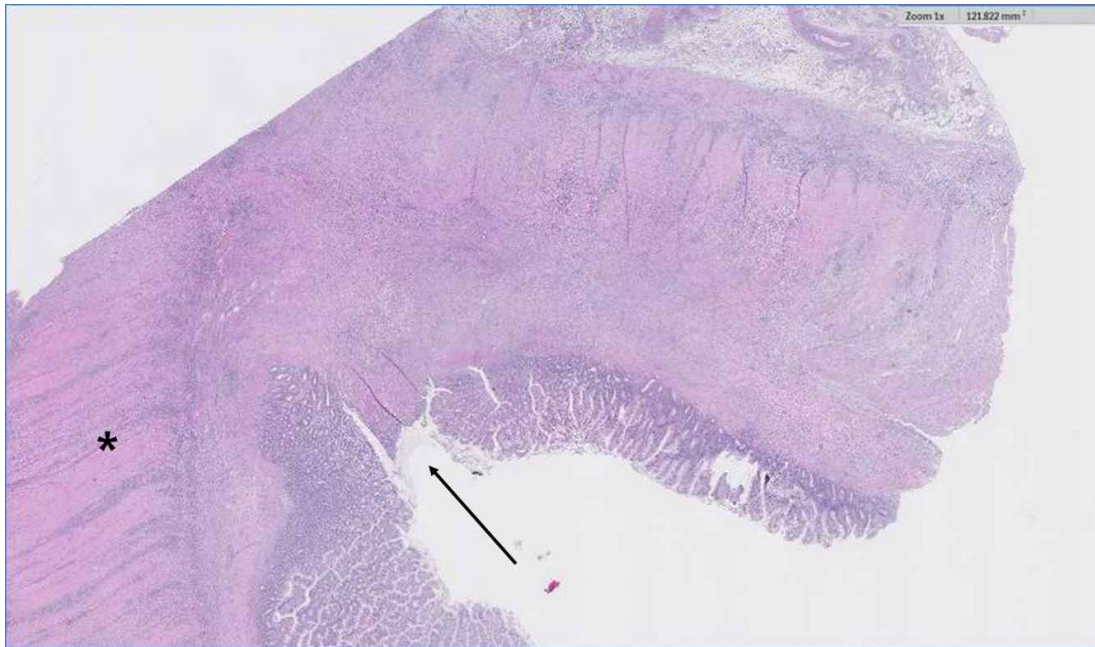

Figure 2. ileocecal stricture in the patient on ultrasonography (A) and resected specimen (B). The original site of lymphoma (arrows) is narrow with marker dilation of the proximal intestine (asterisk).

A



B

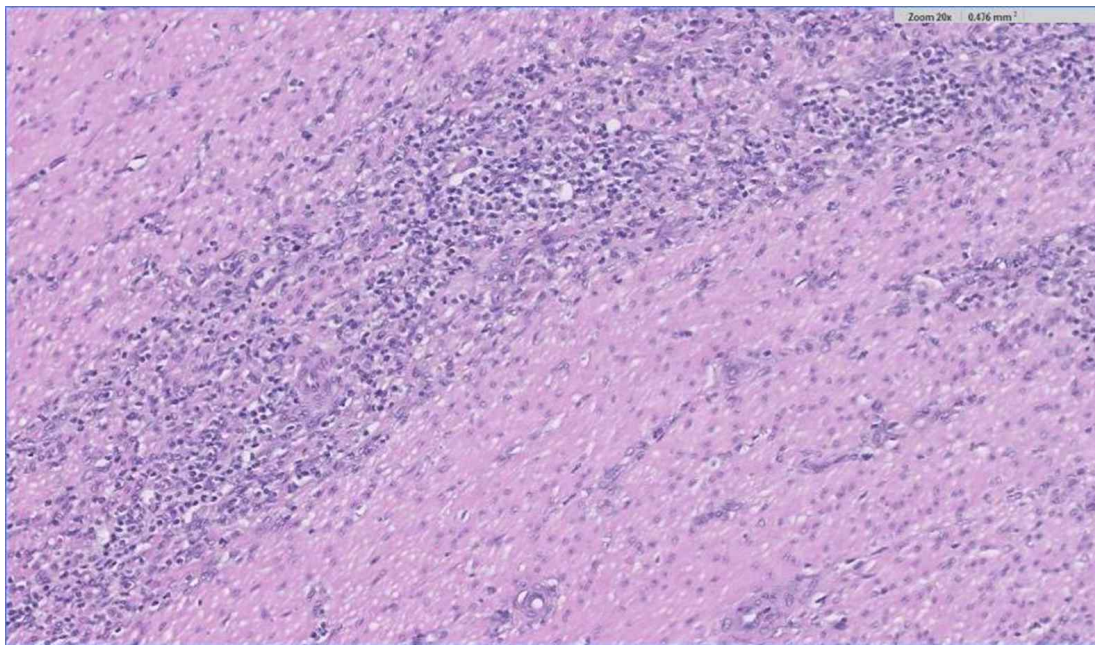


Figure 3. Histological section of the stricture. In (A), there is an area of ulceration within mucosa (arrow). (B) shows a high-resolution image of asterisk on (A). There are transmural mixed inflammatory infiltrates.

After the HGAL lesion was resected, the patient was assumed to be in complete remission. Seven hundred and sixty days after completing CHOP-based chemotherapy, the patient remained in complete remission.

IV. Discussion

Intestinal stricture is an unreported complication of chemotherapy in veterinary medicine. However, in humans, it is regarded as a major complication that may occur during or after gastrointestinal lymphoma chemotherapy [5]. The pathophysiology of postchemotherapy intestinal strictures remains unknown; however, mucosal injury and inflammation have been suggested as probable causes [7, 9]. This patient in the presents case presented to the hospital with melena, indicating severe enteritis. Mucosal injury following chemotherapy could have resulted in excessive and atypical reactions in the already damaged intestine of the patient. Thus, we suggest ulcerative enteritis in patients HGAL is a predisposing factor for intestinal strictures in patients treated wit CHOP-based chemotherapy. Moreover, the innately narrow feature of the ileocecal junction could be considered a predisposing factor for strictures.

Because histopathology in this patient was performed after chemotherapy and surgery, it is difficult to determine whether the intestinal stenosis, resulting in mechanical obstruction, existed before or after chemotherapy. However, lymphoma is unlikely to cause desmoplastic reaction [9]. Additionally, since our patients gastrointestinal symptoms worsened after administration of the second dose of vincristine (3rd week), it is deducible that intestinal stenosis might have progress with the chemotherapy.

In a study by Crouse et al, post-chemotherapy GI perforation occurred in 17% of the feline patients with I/HGAL. In half of these patients with GI perforation, the events occurred within three days after vincristine administration. Our patient was diagnosed with an intestinal stenosis two days after receiving the second dose of vincristine (3rd week). Although this was

observed in only one patient, which hinders generalizability, it is beneficial to closely monitor GI toxicosis in veterinary patients, especially after administration of vincristine.

In feline I/HGAL, the therapeutic impact of surgical excision on survival time compared with chemotherapy alone is unknown. Despite these controversies, this patient was alive at the time of completion of data collection 760 days after the first medical examination. It was longer than the mean survival time (MST) of cats with I/HGAL treated with multiagent combination chemotherapy. Two studies (Gouldin et al. and Tidd et al.) examined the effects of I/HGAL surgery followed by multi-agent chemotherapy. Gouldin et al. found that resectable single primary gastrointestinal tumors, regardless of mesenteric lymph node metastasis, showed better MST and disease-free intervals. Tidd et al. showed that complete surgical resection of a large intestinal mass also resulted in a longer MST. In this patient, there was a resectable single ileal lymphoma at the time of diagnosis with no residual malignant lymphoma on hisopathologic examination. Although the present case differed from the previous two studies wherein surgery was conducted before chemotherapy, this patient also had a good prognosis.

V. Conclusion

To the best of our knowledge, this is the first case of intestinal stenosis which is developed after complete response to CHOP-based chemotherapy in a cat with HGAL. The clinical manifestations of intestinal stenosis such as anorexia, vomiting and lethargy are similar to the common signs of gastrointestinal toxicity following chemotherapy or intestinal lymphoma. Although this is a rare case, intestinal stenosis could be included as a differential diagnosis when patients with HGAL present with gastrointestinal dysfunction after chemotherapy.

VI. References

1. Crouse, Z., Phillips, B., Flory, A., Mahoney, J., Richter, K., & Kidd, L. Post-chemotherapy perforation in cats with discrete intermediate-or large-cell gastrointestinal lymphoma. *Journal of feline medicine and surgery* 2018; 20(8): 696-703.
2. Gieger T. Alimentary lymphoma in cats and dogs. *Vet ClinNorth Am Small Anim Pract* 2011; 41: 419-432.
3. Gouldin, E. D., Mullin, C., Morges, M., Mehler, S. J., de Lorimier, L. -P., Oakley, C., Risbon, R., May, L., Kahn, S. A., & Clifford, C. Feline discrete high-grade gastrointestinal lymphoma treated with surgical resection and adjuvant CHOP-based chemotherapy: retrospective study of 20 cases. *Veterinary and Comparative Oncology* 2017; 15(2): 328-335.
4. Holloway, A., Pivetta, M., & Rasotto, R. Ultrasonographic and histopathological features in 8 cats with fibrotic small intestinal stricture. *Veterinary Radiology & Ultrasound* 2019; 60(4): 423-431.
5. Honzawa, Y., Kondo, M., Hayakumo, T., Matsuura, M., & Nakase, H. Successful endoscopic dilation treatment of small intestinal stricture occurring during chemotherapy for malignant lymphoma. *Case reports in Gastroenterology* 2010; 4(3): 323-329.
6. Kwak, D. H., Cho, M. J., Song, K. H., & Seo, K. W. A retrospective study of 16 cats with intermediate-to high-grade alimentary lymphoma. *Korean Journal of Veterinary Research* 2021; 61(1): 8.1-8.10.
7. Malakounides, G., M. John, S. Sultan, A. Atra and Z. Mukhtar. Laparoscopic surgery for an ileal stricture secondary to chemotherapy in paediatric B-cell non-Hodgkin lymphoma. *Hellenic Journal of Surgery* 2013; 85: 408-413.
8. Louwerens M, London CA, Pedersen NC, et al. Feline lymphoma in the

- post-feline leukemia virus era. *Journal of Veterinary Internal Medicine* 2005; 19: 329-335.
9. Sattavan, S., Aggarwal, L., & Dikshit, P. Uncommon presentation of isolated jejunal lymphoma masquerading as Crohn's disease. *Case Reports in Surgery*, 2016.
 10. Simon, D., Eberle, N., Laacke-Singer, L., & Nolte, I. Combination chemotherapy in feline lymphoma: treatment outcome, tolerability, and duration in 23 cats. *Journal of Veterinary Internal Medicine* 2008; 22(2): 394-400.
 11. Tidd, K. S., A. C. Durham, D. C. Brown, S. Velovolu, J. Nagel and E. L. Krick. Outcomes in 40 cats with discrete intermediate-or large-cell gastrointestinal lymphoma masses treated with surgical mass resection (2005-2015). *Veterinary Surgery* 2019; 48(7): 1218-1228.
 12. Vail DM. Feline lymphoma and leukemia. In: Withrow SJ and Vail DM (eds). *Withrow and MacEwen's small animal clinical oncology*. 4th ed. St Louis, MO: Saunders Elsevier 2007; pp 733-756.

고양이 고도 소화기 림프종에서 항암치료 후 발생한 소화관 협착 증례

홍 현 정

제주대학교 대학원 수의학과

요약

고양이에서 소화기 림프종은 림프종 중에서 가장 많이, 그리고 소화기 종양 중에서 가장 빈번하게 진단되는 종양이다. 미국 국립 암 연구소 (National Cancer Institute Working Formation) 의 기준을 바탕으로 고양이 소화기 림프종은 조직학적으로 저도, 중등도, 고도로 구분한다. 중등도, 고도 소화기 림프종의 경우, 사이클로포스파미드, 독소루비신, 빈크리스틴과 프레드니솔론 병용요법 (CHOP) 으로 대표되는 항암치료로 주로 치료를 시도한다. 중등도, 고도 소화기 림프종을 CHOP 복합 항암요법으로 치료하면서 가벼운 수준의 위장관 증상은 흔히 발생하는 것으로 알려져 있다. 그런데 웨스턴 동물의료센터 (서울, 대한민국) 에 내원한 한 고양이 고도 림프종 환자에서 처음 보는 유형의 위장관 부작용이 CHOP 복합 항암요법 이후 발생하였다.

3살 거세된 수컷 한국 토종 단모종 고양이가 2일간 지속된 기력저하, 식욕부진 그리고 흑변으로 웨스턴 동물의료센터에 내원하였다. 전혈구 검사 상에서 심한 재생성 빈혈이 확인 되었으며, 복부 초음파 상에서 정상적인 소장벽의 구조가 변형된, 저에코의 소장 종괴 (6 × 3.5 cm)가 확인되었다. 세침검사를 통해 고도 소화기 림프종이 진단되었다. CHOP로 항암치료를 하는 도중에 환자는 구토와 기력저하로 응급센터로 내원하였다. 복부 초음파 상에서 소화기 림프종이 위치했던 부분에 소장 협착이 발생한 것이 확인되었다. 기계적 폐색을 해소해주기 위한 수술을 진행했으며 환자는 760일에 이르는 현재까지

완전관해상태를 유지하고 있다. 저자가 아는 한, 이 논문은 고양이의 고도 소화기 림프종에서 CHOP 복합 항암요법 이후에 발생한 소장협착의 첫 번째 증례 보고이다.

주요어: 소화기 림프종, 항암요법, 위장관 협착, 고양이

감사의 글

곁에서 늘 응원해주시고 도와주시는 소중한 분들 덕분에 이 논문을 쓸 수 있었습니다. 한 글자 한 글자에 제 감사한 마음을 눌러 담습니다.

저를 제자로 받아 2년간 세심하게 지도해주신 송우진 교수님께 깊은 감사의 마음을 전합니다. 제자 모두에게 진심으로 대해주시는 모습을 스승으로서 수의사로서 뿐만 아니라 한 사람으로서도 존경합니다. 내과 실험실을 화목하게 이끌어주시고 열정적인 가르침을 주시고 격려해주신 윤영민 교수님께 감사드립니다. 부족한 논문을 다듬어갈 수 있도록 짚어주시고 살펴주신 김명철 교수님께도 감사드립니다.

갓 졸업한, 아무것도 할 줄 모르는 저를 수의사로 길러주신 웨스턴동물의료센터의 모든 인연에 감사합니다. 홍연정 원장님, 박정훈 원장님, 손상준 과장님 감사합니다. 힘든 인턴 시기에 서로의 버팀목이 되어주었던 황호준 선생님을 비롯한 우리 웨스턴 9기 동기들도 감사합니다. 저를 식구로 받아주시고 석사 졸업을 위해 많은 배려해주신 품 동물병원의 모든 선생님들께도 감사드립니다.

석사 과정동안 많이 의지했던 박세영 선생님, 이새영 선생님이 있어서 제주대학교와 석사 생활에 잘 적응하고 마무리할 수 있었습니다. 학부동안 함께 애썼던 용휘와 희정 언니에게도 언제나 고맙게 생각합니다.

딸의 긴 가방끈을 지켜봐주신, 그리고 늘 제 편이 되어주시는 엄마, 아빠 너무나도 존경하고 사랑합니다. 하나 뿐인 오빠와 딸처럼 대해주시는 큰엄마도 제 곁에 있어주어 항상 감사합니다.

끝으로 부족한 제게 주치의로 믿고 맡겨졌던 모든 생명들의 안녕을 빕니다. 고귀한 생명을 다루는 일을 업으로 하는, 그 무게와 어려움을 잊지 않겠습니다. 늘 고민하고 정진하는 수의사가 되도록 노력하겠습니다.

한라산보다도 큰 감사를 담아,

2024년 2월

홍현정