



저작자표시-비영리-변경금지 2.0 대한민국

이용자는 아래의 조건을 따르는 경우에 한하여 자유롭게

- 이 저작물을 복제, 배포, 전송, 전시, 공연 및 방송할 수 있습니다.

다음과 같은 조건을 따라야 합니다:



저작자표시. 귀하는 원저작자를 표시하여야 합니다.



비영리. 귀하는 이 저작물을 영리 목적으로 이용할 수 없습니다.



변경금지. 귀하는 이 저작물을 개작, 변형 또는 가공할 수 없습니다.

- 귀하는, 이 저작물의 재이용이나 배포의 경우, 이 저작물에 적용된 이용허락조건을 명확하게 나타내어야 합니다.
- 저작권자로부터 별도의 허가를 받으면 이러한 조건들은 적용되지 않습니다.

저작권법에 따른 이용자의 권리는 위의 내용에 의하여 영향을 받지 않습니다.

이것은 [이용허락규약\(Legal Code\)](#)을 이해하기 쉽게 요약한 것입니다.

[Disclaimer](#)

A Thesis  
For the Degree of Master of Veterinary Medicine

The First Case of Cecal  
Malignant Peripheral Nerve  
Sheath Tumor in a Dog

Department of Veterinary Medicine  
GRADUATE SCHOOL  
JEJU NATIONAL UNIVERSITY

Hye Rin Ahn

2023.02

# The First Case of Cecal Malignant Peripheral Nerve Sheath Tumor in a Dog

Hye Rin Ahn

(Supervised by Professor Woo-Jin Song)

A Thesis submitted in partial fulfillment of the requirement for the  
Degree of Master of Veterinary Medicine

2022.12

This thesis has been examined and approved by

---

Thesis director, YoungMin Yun, DVM, Ph.D, Prof. of Department of Veterinary Medicine

---

Jae-Hoon Kim, DVM, Ph.D, Prof. of Department of Veterinary Medicine

---

Thesis supervisor Woo-Jin Song DVM, Ph.D, Prof. of Department of Veterinary Medicine

2022.12.

Department of Veterinary Medicine  
GRADUATE SCHOOL  
JEJU NATIONAL UNIVERSITY

Abstract

# The First Case of Cecal Malignant Peripheral Nerve Sheath Tumor in a Dog

Hye Rin Ahn

(Supervised by professor Woo-Jin Song)

Department of Veterinary Medicine

GRADUATE SCHOOL

JEJU NATIONAL UNIVERSITY

A 12-year-old mixed-breed dog presented with a 2-month history of abdominal distension. Radiographic examination, abdominal ultrasonography and computed tomography revealed a mass in the cecum ( $15.0 \times 11.9 \times 4.5$  cm). The cecal mass was surgically removed and examined histopathologically. Immunohistochemically, the neoplastic cells expressed S-100 and neuron specific enolase but not  $\alpha$ -smooth muscle actin and CD117 (c-kit). These histologic and immunohistochemical features indicated that the mass was consistent with a malignant peripheral nerve sheath tumor (MPNST). In dogs, most MPNSTs arise from the brachial plexus, spinal nerve root, and skin of the extremities. However, gastrointestinal MPNSTs in dogs have not been described previously. To the best of my knowledge, this is the first report to describe cecal MPNST in a dog. MPNST might be included in differential diagnostic lists of gastrointestinal mass.

---

***Key words:*** cecal mass, dog, gastrointestinal mass, immunohistochemistry, malignant peripheral nerve sheath tumor.

## Contents

I. Introduction .....	1
II. Materials and Methods .....	2
III. Results .....	4
IV. Discussion .....	6
V. Clinical relevance .....	8
VI. References .....	9
국문 초록 .....	17

## I. Introduction

Peripheral nerve sheath tumors (PNSTs) are generally classified as soft tissue tumors that usually arise from Schwann cells, perineural cells, fibroblasts, or other cells comprising the nerve sheaths. PNSTs may be subdivided into benign and malignant PNST (MPNST) variants [24]. Schwannomas and neurofibromas are the most common types of human benign PNSTs. Most MPNSTs in humans are localized in the trunk, head, neck, extremities, and paravertebral regions. [12, 24] MPNSTs of the gastrointestinal tract are rare [12]. Only 6 cases were observed to originate from the colon, and MPNST of the cecum has not been reported previously to my knowledge [17]. The relationship between MPNST and neurofibromatosis 1 (NF1) is well known in humans. Neurofibromatosis is an autosomal dominant disorder, and up to 50% of MPNSTs are associated with NF1. NF1-related MPNSTs reportedly have a worse prognosis than non-NF1-related MPNST [5, 6, 11, 25].

In dogs, most MPNSTs arise from the brachial plexus, spinal nerve root, and skin of the extremities [4, 8, 23]. Canine MPNSTs have also been reported in other uncommon sites, such as the liver, spleen, adrenal gland, bladder, and diaphragm [1, 7, 10, 14, 15]. Two cases of benign PNSTs in the gastrointestinal tract were reported previously [21]. However, gastrointestinal MPNSTs in dogs have not been described previously. To the best of my knowledge, this is the first report of MPNST originating from the cecum in a dog.

## II. Materials and Methods

### *Patient*

A 12-year-old 5.6 kg neutered male mixed-breed dog with a 2-month history of abdominal distension was presented to the Veterinary Medical Teaching Hospital, College of Veterinary Medicine, Jeju National University in the Republic of Korea. Physical examination revealed a body condition score of 4/9, and the abdomen was markedly distended.

### *Laboratory examination*

Laboratory evaluations included a complete blood count (CBC) (Advia 2120i; Siemens, Erlangen, Germany), assessment of serum chemistry (Vetscan; Abaxis, CA, USA) and PT and APTT were evaluated using an automated coagulation analyzer (VetScan VSpro; Abaxis).

### *Imaging examination*

The abdominal and thoracic radiographs were obtained using digital radiographic equipment (Listem, Seoul, Korea). Abdominal mass were evaluated by ultrasonography (Philips, Bothell, WA, USA) and Computed tomography (Somatom Emotion; Siemens).



### *Pathologic examinations*

Tissue samples were stained with hematoxylin and eosin and immunochemistry at the laboratory of Veterinary Pathology in Jeju National University. For immunohistochemical analysis, a panel of 4 antibodies, including S-100 (DAKO, Denmark), neuron specific enolase (NSE; DAKO),  $\alpha$ -smooth muscle actin ( $\alpha$ -SMA; DAKO) and CD117 (c-kit; DAKO).

### III. Results

The biochemical profile and complete blood count were normal. On the radiographic view, a large, round, soft tissue opaque mass was visualized in the ventral abdomen, and it was difficult to make the evaluation of the dorsocaudal part of the abdomen (Fig. 1). Abdominal ultrasonography revealed a large, heterogeneous echotexture mass (Fig. 2). Ultrasound-guided fine-needle aspiration of the abdominal mass revealed low cellularity with mesenchymal cells. Preoperative and post-contrast-enhanced computed tomography of the abdomen was performed for surgical planning.

A soft tissue-attenuating large mass (15.0 × 11.9 × 4.5 cm) was noted within the middle of the abdomen. A segment presumed to be the cecum was embedded from the back to the inside of the mass, which had relatively distinct margins (Fig. 3). An exploratory laparotomy was performed for diagnostic and therapeutic purposes. The dog was premedicated with 0.2 mg/kg intravenous midazolam (Bukwang Midazolam; Bukwang Pharm, Seoul, Korea) and anesthetic induction was achieved by injecting 6 mg/kg propofol (Anepol; Hana Pharm, Seoul, Korea) intravenously; it was maintained with isoflurane and oxygen (1.5–1.8% concentration of isoflurane in oxygen). A large, firm, and well-circumscribed round cecal mass weighing approximately 1.6 kg (approximately 28% of the body mass) was surgically resected (Fig. 4A) and submitted for histopathology. The samples were routinely processed for histopathology and stained with hematoxylin and eosin. The mass consisted of a population of neoplastic spindle cells present in the interwoven bundle that formed a herringbone pattern (Fig. 4B). Neoplastic cells exhibited hyperchromatic nuclei, and mild nuclear pleomorphism. Mitotic figures counted

in 10 high power fields (2.37 mm<sup>2</sup>) (diameter of the field of view = 0.55 mm; 40× objective and 10× ocular field number (FN) 22 mm; Olympus BX43 microscope) were 0-1.

Immunohistochemically, the neoplastic cells were positive for S-100 and NSE and negative for α-SMA and CD117 (c-kit). Based on these histopathologic and immunohistochemical features, the mass was diagnosed as a malignant neoplasm of peripheral nerve sheath origin (Fig. 5 A-D). The dog was discharged from the hospital 9 days postoperatively. Further adjuvant chemotherapy and recheck ultrasonography for the cecum tumor were proposed but declined by the owner. The dog remained well for more than 400 days, however, died 478 days after surgery due to tumor recurrence.

## IV. Discussion

Gastrointestinal MPNSTs are rarely reported in cats, and only two cases have been reported to my knowledge [2, 18]. Ribas *et al.* reported a small intestinal MPNST without metastasis in a 5-year-old female spayed chinchilla cat that was treated with complete surgical excision. The cat remained free from clinical signs for up to six months [18]. Boland *et al.* described a colonic MPNST with hepatic metastasis in a 14-year-old male neutered domestic medium-hair cat that was treated with surgical resection and metronomic cyclophosphamide. The cat experienced recurrence, and post-mortem examination identified MPNST within the kidneys and liver 18 months postoperatively [2].

The diagnosis of MPNST is often difficult, because it is a diverse group of heterogeneous neoplasms. Histologically, MPNST are usually highly infiltrative lesions composed of pleomorphic spindle cells with ovoid or fusiform cells mostly arranged in interwoven bundles, palisades and whorls. [19, 20]. Immunohistochemistry is mainly used to confirm the neural origin and exclude other possible spindle cell tumors. But It has not yet been a clear diagnostic criteria for MPNST. S-100, NSE, Vimentin, nerve growth factor receptor (NGFR) and oligodendrocyte transcription factor 2 (Olig2) were suggested as MPNST markers [7, 20]. Although I could not perform immunohistochemistry using more neurologic markers such as vimentin, NGFR or Olig2 [7, 20], expression levels of S-100 protein and NSE which are highly related to neural-derived neoplasia [8, 13] were evaluated in this study. In addition, different markers are used to exclude other possible non-angiogenic, non-lymphogenic intestinal mesenchymal tumors [13].  $\alpha$ -SMA and desmin are used to rule out smooth muscle tumors, whereas CD117

(c-kit) and CD34 are used to rule out gastrointestinal stromal tumors [2, 8, 18, 20]. In this case, I observed positivity for S-100 protein and NSE and negativity for c-kit and  $\alpha$ -SMA.

Current treatment of MPNST in humans is similar to that of soft tissue sarcomas (STS). Complete surgical excision with wide negative margins is treatment of choice [9, 16]. The role of adjuvant radiotherapy and chemotherapy remains controversial. However, postoperative radiotherapy is often recommended to improve local control, especially after incomplete resection. No randomized trials have assessed the efficacy of specific adjuvant chemotherapy in MPNST [5, 6, 16, 17, 24]. However, Kroep *et al.* compared chemotherapy for MPNST and other STSs and reported similar outcomes. The retrospective data from 12 pooled trials indicated that a doxorubicin-ifosfamide combination was associated with a lower risk of relapse and better response rate [9]. Wang *et al.* reported that a patient with multiple metastatic NF-1 related MPNSTs was administered combination chemotherapy with ifosfamide, carboplatin, and etoposide, known as ICE chemotherapy after the primary lesion was resected. It has been 12 years since his first visit, and he remains disease-free [25]. Chaudhary and Borker described a case of a 10-year-old male dog with MPNST with NF-1 who achieved a complete response to metronomic therapy with etoposide, cyclophosphamide, and prednisolone [5].

Only a few instances of metronomic therapy as MPNST treatment have been reported for dogs and cats. Metronomic therapy with cyclophosphamide and piroxicam delays recurrence in dogs after incomplete surgical excision [3, 22]. In addition, in a cat with colonic MPNST treated with surgery and metronomic cyclophosphamide, clinical signs recurred 18 months postoperatively [2]. However, the optimal treatment for gastrointestinal MPNST remains poorly established due to its rare occurrence.

## V. Clinical relevance

To my knowledge, this is the first reported case of cecum MPNST in a dog. The dog remained free of clinical signs for 12 months postoperatively without adjuvant chemotherapy.

## VI. References

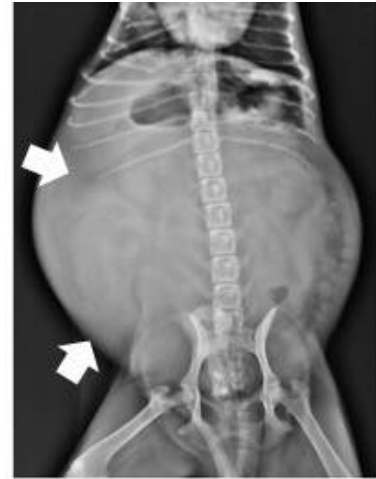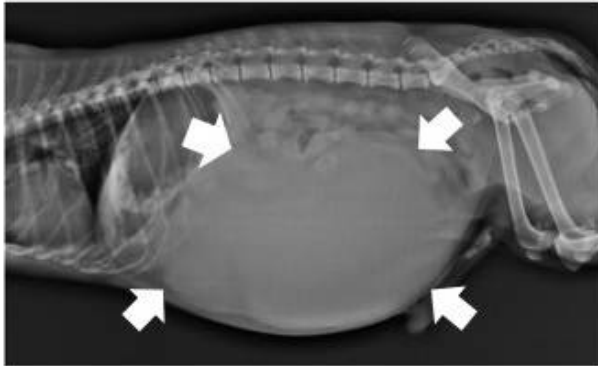
1. Bergmann W, Burgener IA, Roccabianca P, Rytz U, Welle M. 2009. Primary splenic peripheral nerve sheath tumour in a dog. *J Comp Pathol* 141: 195-198.
2. Boland L, Setyo L, Sangster C, Brunel L, Foo T, Bennett P. 2019. Colonic malignant peripheral nerve sheath tumour in a cat. *JFMS Open Rep* 5: 2055116919849979.
3. Briffod C, Hélie P, De Lasalle J, de Lorimier LP, Moreau AR, Alves DA, Vanore M. 2018. Retrobulbar malignant peripheral nerve sheath tumor in a golden retriever dog: a challenging diagnosis. *Can Vet J* 59: 379-384.
4. Brower A, Salamat S, Crawford J, Manley P. 2005. Unilateral limb enlargement in a dog with a malignant peripheral nerve sheath tumor. *Vet Pathol* 42: 353-356.
5. Chaudhary N, Borker A. 2012. Metronomic therapy for malignant peripheral nerve sheath tumor in neurofibromatosis type 1. *Pediatr Blood Cancer* 59: 1317-1319.
6. Farid M, Demicco EG, Garcia R, Ahn L, Merola PR, Cioffi A, Maki RG. 2014. Malignant peripheral nerve sheath tumors. *Oncologist* 19: 193-201.
7. Ichikawa M, Suzuki S, Tei M, Nibe K, Uchida K, Ono K, Hirao H. 2018. Malignant peripheral nerve sheath tumor originating from the adrenal gland in a dog. *J Vet Med Sci* 80: 1572-1575.
8. Ko SB, Song KO, Kang SC, Kim JH. 2014. Cutaneous peripheral nerve sheath tumors in 15 dogs. *Korean J Vet Res* 54: 7-12.
9. Kroep JR, Ouali M, Gelderblom H, Le Cesne A, Dekker TJA, Van Glabbeke M, Hogendoorn PCW, Hohenberger P. 2011. First-line chemotherapy for malignant peripheral nerve sheath tumor (MPNST)

versus other histological soft tissue sarcoma subtypes and as a prognostic factor for MPNST: an EORTC soft tissue and bone sarcoma group study. *Ann Oncol* 22: 207-214.

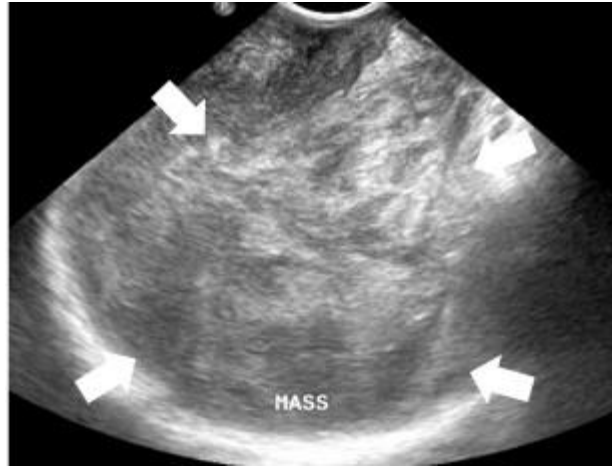
10. Lee SW, Baek SM, Lee AR, Kim TU, Kim D, Kwon YS, Yun S, Park SJ, Hong IH, Jeong KS, Park JK. 2020. Malignant peripheral nerve sheath tumour in the urinary bladder of a dog. *J Comp Pathol* 175: 64-68.
11. Lee YJ, Moon H, Park ST, Ha WS, Choi SG, Hong SC, Joo YT, Jeong CY, Jung EJ. 2006. Malignant peripheral nerve sheath tumor arising from the colon in a newborn: report of a case and review of the literatures. *J Pediatr Surg* 41: e19-22.
12. Mohtaram A, Mesmoudi S, M'rabti H, Rami A, Latib R, Bernoussi Z, Aaribi I, Ben Ameer El Youbi M, Errihani H. 2013. Malignant peripheral nerve sheath tumor of the small bowel: an unusual presentation with fatal outcome. *Case Rep Oncol Med* 2013: 423867.
13. Munday JS, Löhr CV, Kiupel M. 2017. Chapter 13. Tumors of the alimentary tract. pp. 499-601. In: *Tumors in Domestic Animals*, 5th ed. (Meuten DJ ed.), Wiley-Blackwell, Hoboken.
14. Park JW, Woo GH, Jee H, Jung DW, Youn HY, Choi MC, Kim DY. 2011. Malignant peripheral nerve sheath tumour in the liver of a dog. *J Comp Pathol* 144: 223-226.
15. Patterson CC, Perry RL, Steficek B. 2008. Malignant peripheral nerve sheath tumor of the diaphragm in a dog. *J Am Anim Hosp Assoc* 44: 36-40.
16. Pervaiz N, Colterjohn N, Farrokhyar F, Tozer R, Figueredo A, Ghert M. 2008. A systematic meta-analysis of randomized controlled trials of adjuvant chemotherapy for localized resectable soft-tissue sarcoma. *Cancer* 113: 573-581.
17. Rawal G, Zaheer S, Ahluwalia C, Dhawan I. 2019. Malignant peripheral nerve sheath tumor of the transverse colon with peritoneal metastasis: a



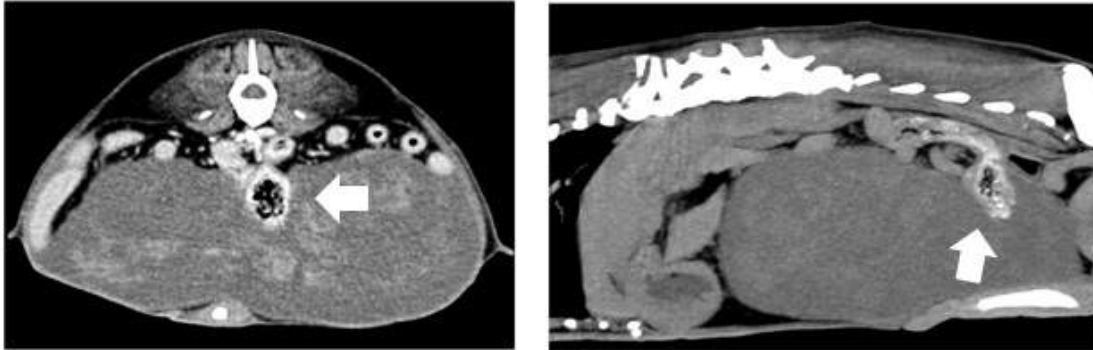
- case report. *J Med Case Reports* 13: 15.
18. Ribas A, Miller R, Rasotto R. 2017. Small intestinal peripheral nerve sheath tumour in a cat. *JFMS Open Rep* 3: 2055116917710394.
  19. Rodriguez FJ, Folpe AL, Giannini C, Perry A. 2012. Pathology of peripheral nerve sheath tumors: diagnostic overview and update on selected diagnostic problems. *Acta Neuropathol* 123: 295-319.
  20. Rubina S, Silvia S, Giuliano B, Luciana M. 2016. Reclassification of 21 presumptive canine peripheral nerve sheath tumors (pnst) using a literature-based immunohistochemical panel. *Acta Vet (Beogr)* 66: 455-465.
  21. Schöniger S, Summers BA. 2009. Localized, plexiform, diffuse, and other variants of neurofibroma in 12 dogs, 2 horses, and a chicken. *Vet Pathol* 46: 904-915.
  22. Son JN, Park SK, Choi SH, Kim GH. 2011. Treatment of malignant peripheral nerve sheath tumor using surgery and metronomic chemotherapy in a dog. *J Vet Clin* 28: 310-313.
  23. Suzuki S, Uchida K, Nakayama H. 2014. The effects of tumor location on diagnostic criteria for canine malignant peripheral nerve sheath tumors (MPNSTs) and the markers for distinction between canine MPNSTs and canine perivascular wall tumors. *Vet Pathol* 51: 722-736.
  24. Thway K, Fisher C. 2014. Malignant peripheral nerve sheath tumor: pathology and genetics. *Ann Diagn Pathol* 18: 109-116.
  25. Wang Y, Katagiri H, Murata H, Wasa J, Miyagi M, Kakuda Y, Takahashi M. 2020. Metastatic malignant peripheral nerve sheath tumor with NF1 successfully treated with 'gradual subtraction' ICE chemotherapy. *Anticancer Res* 40: 1619-1624.



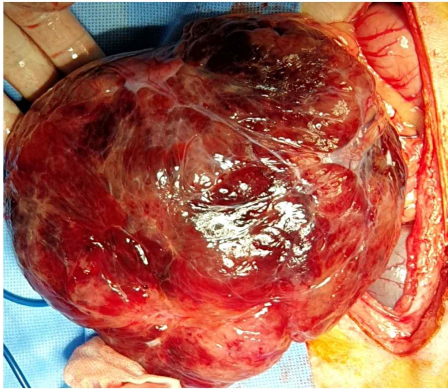
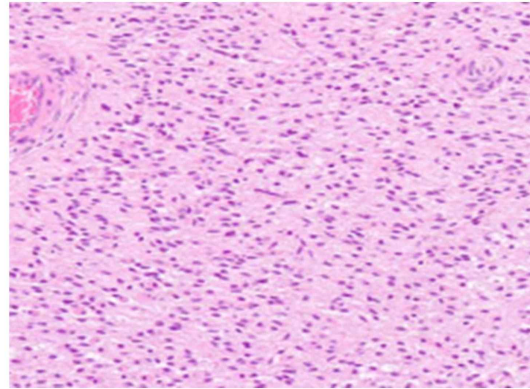
**Fig. 1. Radiographic images of the right lateral view and dorso-ventral view.** A large, round, soft tissue opaque mass (white arrow) was visualized in the ventral abdomen.



**Fig. 2. Sagittal ultrasound image of the mass.** Abdominal ultrasonography revealed a large, heterogeneous echotexture mass (white arrow).



**Fig. 3.** Computed tomography of the transverse and sagittal view fo the abdomen. A soft tissue-attenuating large mass (15.0 × 11.9 × 4.5 cm) was noted within the middle of the abdomen. A segment presumed to be the cecum (white arrow) was embedded from the back to the inside of the mass.

**A****B**

**Fig. 4. Intraoperative image of the cecal mass and histopathology with hematoxylin and eosin staining of the mass. (A) A large, firm, and well-circumscribed round cecal mass weighing approximately 28% of the body mass. (B) The mass consisted of a population of neoplastic spindle cells present in the interwoven bundle that formed a herringbone pattern ( $\times 200$ ).**

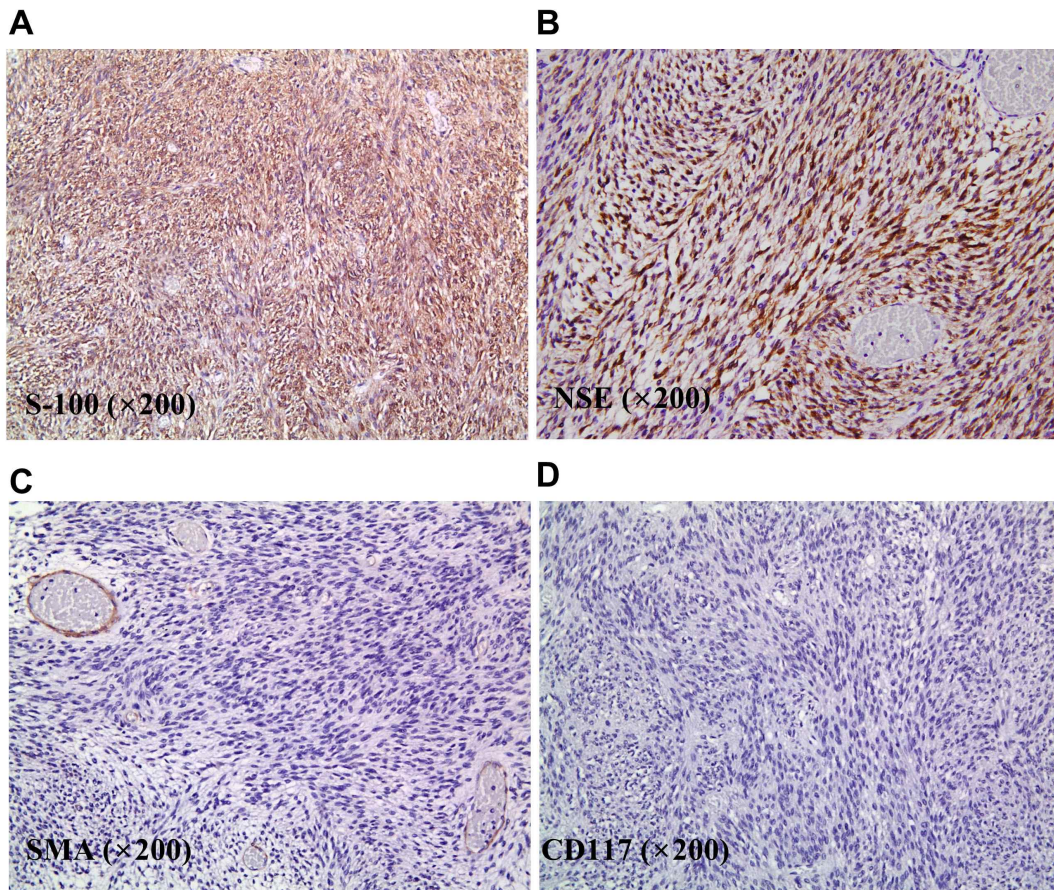


Fig. 5. Immunohistochemical staining of the neoplastic cells in the tumor ( $\times 200$ ). The neoplastic cells are positive for (A) S-100, (B) neuron specific enolase, and (C) negative for  $\alpha$ -smooth muscle actin, and (D) CD117.

국문 초록

# 개의 맹장유래 악성 말초신경집 종양의 첫 증례

안혜린

(지도교수: 송우진)

제주대학교 대학원 수의학과

12살 잡종견이 2달간의 복부 팽만을 주증상으로 내원하였고 방사선검사, 복부 초음파 및 CT 촬영을 통해 맹장 종괴를 확인하였다. 맹장 종괴를 수술적으로 제거하고 조직병리학적 검사를 수행하였다. 맹장 종괴를 구성하는 방추형의 종양세포들에 대한 면역조직화학 염색 결과 S-100, neuron specific enolase는 양성,  $\alpha$ -smooth muscle actin, CD117 (c-kit)은 음성을 나타내었다. 면역조직화학적 특징을 토대로 맹장 종괴는 악성 말초신경집 종양으로 진단하였다. 개에서 대부분의 악성 말초신경집 종양은 상완신경총, 척수 신경 뿌리, 사지의 피부에서 발생하지만 개에서 위장관 유래 악성 말초신경집 종양은 아직까지 보고된 바 없다. 이 논문은 개의 맹장에서 유래한 악성 말초신경집 종양의 첫 번째 증례 보고이다. 따라서 개의 위장관 내 종괴가 발생하였을 경우 악성 말초신경집 종양도 감별 진단 대상 종양으로 고려되어야 할 것으로 사료된다.

---

**Key words:** 개, 맹장종괴, 면역조직화학 염색법, 악성 말초신경집종양, 위장관  
종괴