



저작자표시-비영리-변경금지 2.0 대한민국

이용자는 아래의 조건을 따르는 경우에 한하여 자유롭게

- 이 저작물을 복제, 배포, 전송, 전시, 공연 및 방송할 수 있습니다.

다음과 같은 조건을 따라야 합니다:



저작자표시. 귀하는 원저작자를 표시하여야 합니다.



비영리. 귀하는 이 저작물을 영리 목적으로 이용할 수 없습니다.



변경금지. 귀하는 이 저작물을 개작, 변형 또는 가공할 수 없습니다.

- 귀하는, 이 저작물의 재이용이나 배포의 경우, 이 저작물에 적용된 이용허락조건을 명확하게 나타내어야 합니다.
- 저작권자로부터 별도의 허가를 받으면 이러한 조건들은 적용되지 않습니다.

저작권법에 따른 이용자의 권리는 위의 내용에 의하여 영향을 받지 않습니다.

이것은 [이용허락규약\(Legal Code\)](#)을 이해하기 쉽게 요약한 것입니다.

[Disclaimer](#)

碩士學位論文

關節鏡적 回轉筋蓋 復元術 施行 前
斜角筋間 上腕神經叢 遮斷術이
手術 中에 미치는 影響

濟州大學校 大學院

醫學科

金泰廷

2016年 2月

관절경적 회전근개 복원술 시행 전
사각근간 상완신경총 차단술이
수술 중에 미치는 영향

지도교수 최 성 욱

김 태 정

이 논문을 의학 석사학위 논문으로 제출함

2015年 12月

김태정의 의학 석사학위 논문을 인준함

심사위원장 이 근 화 ㉠

위 원 장 원 영 ㉠

위 원 최 성 욱 ㉠

제주대학교 대학원

2015年 12月

Intraoperative effect of Interscalene brachial
plexus block to Arthroscopic Rotator cuff
repair surgery

Taejung Kim
(Supervised by professor Sungwook Choi)

A thesis submitted in partial fulfillment of the requirement for
the degree of Master of Science [Orthopaedic surgery]

2015. 12.

This thesis has been examined and approved.

Doctoral Committee :

Professor Keun Hwa Lee Chairman
Weon Young Chang
Sungwook Choi

Department of Orthopaedic Surgery
GRADUATE SCHOOL
JEJU NATIONAL UNIVERSITY

목 차

1. Abstract	-----	2
2. Introduction	-----	4
3. Material and Methods	-----	6
4. Result	-----	12
5. Discussion	-----	16
6. Conclusion	-----	20
7. Reference	-----	21

Abstract

Purpose : To determine whether the placement of an interscalene brachial plexus block (IBPB) with general anesthesia before arthroscopic rotator cuff repair surgery would be effective in establishing a clear visual field during surgery and shortening the duration of the procedure.

Methods : This study included 152 patients who had undergone arthroscopic rotator cuff repair. Group A received an IBPB before general anesthesia, and group B did not receive the IBPB. The systolic blood pressure (SBP), diastolic blood pressure (DBP), and heart rate (HR) were recorded. The surgical procedure was divided into four stages, and the duration of each stage was recorded. A visual clarity scale (VCS) was determined by arthroscopic visualization and technical ease. VCS and the medication that was administered intra-operatively for hemodynamic stability were recorded.

Results : The VCS was significantly improved in group A at stage 2 (acromioplasty) and stage 3 (Greater tuberosity and tendon preparation) of the surgical procedures ($P < 0.05$). There was no significant difference between the stage 1 (intra-articular soft tissue procedure, $p = 0.288$) and stage 4 (tendon repair with suture bridge, $p = 0.062$). SBP and DBP were elevated, and HR was increased significantly in group B at all stages ($P < 0.05$). The administered analgesics were significantly higher in group B ($p = 0.003$), but there were no differences in administered hypotensive agents ($p = 0.287$). No significant difference was observed for the duration of the surgery ($p = 0.704$).

Conclusions : Preoperative IBPB with general anesthesia for arthroscopic rotator cuff repair was beneficial in maintaining hemodynamic stability and improving the VCS during surgery.

Introduction

Clear view is one of many important factors in successful arthroscopic shoulder procedures^[1]. Arthroscopy of the subacromial space has two unique aspects: 1) Unable to use tourniquete, 2) No existence of synovial lining to restrict fluid extravasation^[2]. Epinephrine-mixed saline irrigation, application of infusion flow or pressure control systems and hypotensive anesthesia have been used to establish a bloodless field during surgical intervention. A clear visual field is obtained by maintaining a pressure difference between the patient's systolic blood pressure (SBP) and the subacromial space of less than 49 mmHg^[2]. Therefore, it is important to have an effective method for maintaining lower blood pressure and minimizing intra-operative hemodynamic changes.

Increased sympathetic nerve activity is an initial response to painful stimuli^[3]. The degree of pain correlates with increases in blood pressure and vascular resistance^[4]. Pre-emptive analgesia blocks the transmission of noxious efferent information from the peripheral nervous system to spinal cord and brain^[5]. Analgesic agents must be given before the incision and must be of sufficient magnitude to limit sensitization of the nervous system^[6].

The shoulder area is innervated by nerves of both the cervical and brachial plexuses from C5-T1 nerve roots. The interscalene approach to the brachial plexus is best suited for surgery of the shoulder with a block of the lower cervical plexus^[7]. Interscalene brachial plexus block (IBPB) anesthesia has been widely used, with or without general anesthesia, in patients undergoing shoulder surgery^[8]. Hemodynamic stability can be achieved by performing an IBPB, which can not only prevent excessive blood pressure elevation but also maintain a clear operative

view by keeping a balance between intra-articular pressure and systolic blood pressure.

The purpose of this study is to compare the efficiency of general anesthesia alone and general anesthesia with interscalene block while performing arthroscopic rotator cuff repair. We hypothesize that interscalene block with general anesthesia would be more effective than general anesthesia alone in reducing surgical times and establishing clearer visual field during surgery.

Materials and Methods

Patient selection

We identified total 457 patients who had undergone arthroscopic rotator cuff repair surgery from April 2012 to March 2014. After obtaining approval from our institutional review board, the study was progressed after receiving informed consent of the purpose, risks, and complications of this study from each patient.

Study subjects were limited to patients who underwent rotator cuff repair for medium-sized tears. The tear sizes were evaluated by preoperative shoulder MRI and categorized into small (<1 cm), medium (1 to 3 cm), large (3 to 5 cm), and massive (>5 cm), according to the classification of DeOrio and Cofield^[9].

Subjects who had hypertension, coagulopathy, IBPB failure or a history of cardiovascular disease or who were taking drugs that may affect their blood coagulation cascade were excluded from the study (Table 1). The IBPB failure was defined as immediate post operative visual analogue scale (VAS) pain score higher than 4 point. Finally, a total of 152 arthroscopic rotator cuff repair surgeries for medium cuff tears were included in the study.

All subjects were randomly assigned to the following two groups using a random number table by the anesthesiologist: a group that received an IBPB before general anesthesia (Group A, n=73) and a group that did not undergo an IBPB before general anesthesia (Group B, n=79).

Table 1. Inclusion and Exclusion criteria

Inclusion criteria	Exclusion criteria
Full-thickness tear	Long head of biceps brachii disease
Medium sized tear	Partial tears at surgery
Primary repair	Small and large to massive sized tear
	Subsequent surgery in the same shoulder
	Hypertension
	Coagulopathy
	History of cardiovascular disease
	Medication (affect blood coagulation cascade)
	IBPB failure

Interscalene brachial plexus block technique

Patients in the group A received the IBPB in the anesthesia induction room where was separated from operation room. After supine positioning with head rotation to the other side, IBPB was performed with ultrasound and nerve stimulation. The brachial plexus was identified using a nerve stimulator (Stimuplex-S, B. Braun Melsungen AG, Melsungen, Germany) connected to the proximal end of the metal inner needle of a plastic cannula (Stimuplex-A, 25 - G B. Braun Melsungen). The initial current output of the nerve stimulator was 0.7 mA. A linear high frequency 6 - 13 MHz ultrasound probe (Sonosite M-turbo, SonoSite, Inc., Bothell, WA, USA) was used. Upon contraction of the triceps muscle, the C5 - 6 nerve root or superior trunk was found, and 0.25% ropivacaine 10 ml with epinephrine 200 mcg was injected. Patients were transferred to the operating room for induction of general anesthesia and surgery.

General anesthesia technique

Prior to the IV administration of medication for general anesthesia, manual ventilation with O₂ (6L/min) via facial mask was done to all patients. General anesthesia was induced by IV administration of thiopental (5mg/kg) and rocuronium (1mg/kg). And then orotracheal intubation was facilitated. Anesthesia was maintained using a 1.5 minimal alveolar concentration (MAC) of sevoflurane with each 1 L/min of O₂ and N₂O, without using any additional analgesic agents including opioid. Anesthesia was maintained to keep bispectral index (BIS) values from 40 to 60 throughout the surgical procedures. After termination of the operation, reversal agents (glycopyrolate and neostigmine) were administered intravenously prior to extubation^[10].

Surgical technique

The operations were performed by two surgeons, under blind circumstance which patients have received IBPB. Surgery was performed in the lateral decubitus position with the affected shoulder exposed. Epinephrine-mixed saline (1 mL of 1:1000 epinephrine/3000 mL of saline bag) was used for intra-articular irrigation fluid during the surgical procedures. The irrigation fluid was infused via pressure-controlled pump (Linvatec, Lagrigo, FL, USA) set to 50 mmHg. Arthroscopic exam of glenohumeral joint was performed, and any pathologic lesions were identified. After the glenohumeral joint procedure, arthroscopic examination of subacromial space was followed. Subacromial decompression and acromioplasty was performed in all patients. Tear size, tendon quality, and delamination of rotator cuff were assessed. Retracted tendon was released from adhesion for tendon mobilization, and the footprint of the greater tuberosity was decorticated. At the medial edge of the footprint, medial row anchors (3.7 mm & 4.5 mm Bio-

Corkscrew suture anchor, Arthrex, Naples, FL, USA) were inserted. The suturing devices, Scorpion (Arthrex) or Suture hook (Linvatec, Large, FL, USA) were used to pass the fiber-wire through the tendon, closed to the musculotendinous junction of supraspinatus. Medial row knots were tied and the retracted tendon was reduced into the footprint of greater tuberosity. Lateral row anchors (3.5 mm & 4.5 mm, SwiveLock, Arthrex) were inserted 5-10 mm below the greater tuberosity after preparing the bone sockets^[11].

Data collection

The blood pressure was measured using an automatic blood pressure cuff on the uninvolved extremity and the heart rate was measured by an ECG monitor. The SBP, diastolic blood pressure (DBP), and heart rate (HR) were recorded every 5 minutes during the surgery. The anesthesiologist controlled the blood pressure using a combination of analgesics such as 2µg/kg of fentanyl and hypotensive agents such as 10mg of esmolol and 5mg of labetalol. The anesthesiologist generally administered medications to reduce systolic blood pressure if the systolic blood pressure exceeded 140 mmHg throughout the operation. The frequency of administered medication were defined the number of time that medication was given.

The surgical procedure was divided into 4 stages: 1) Intra-articular soft tissue procedure, 2) Acromioplasty, 3) Greater tuberosity and tendon preparation, and 4) Tendon repair with suture bridge. The duration of each surgical procedure and the amount of medication administered for hemodynamic stability were recorded.

During the arthroscopic procedure, the surgeon scored the visual clarity scale (VCS) according to visualization and surgical working conditions at each stage of the surgical procedure. The VCS score ranged from 1 (extremely poor conditions)

to 5 (optimal conditions) (Table 2, Fig 1). Each time of the surgeon rated the VCS, the surgical first assistant asked to give a rating the VCS score using the same five-point scale as used by the surgeon.

Table 2. The visual clarity scale (VCS)

Score	Description
1	Extremely poor Unable to work because of the inability to obtain a visible field by massive bleeding in the surgical field
2	Poor Severely hampered by bleeding requiring cauterization and additional administration of medication for lowering blood pressure or increasing pressure of operative space
3	Acceptable Some impairment during procedure by bleeding requiring only cauterization in the surgical field
4	Good No impairment of procedure with visualization of some bleeding without cauterization
5	Optimal No impairment of procedure without any visualization of bleeding

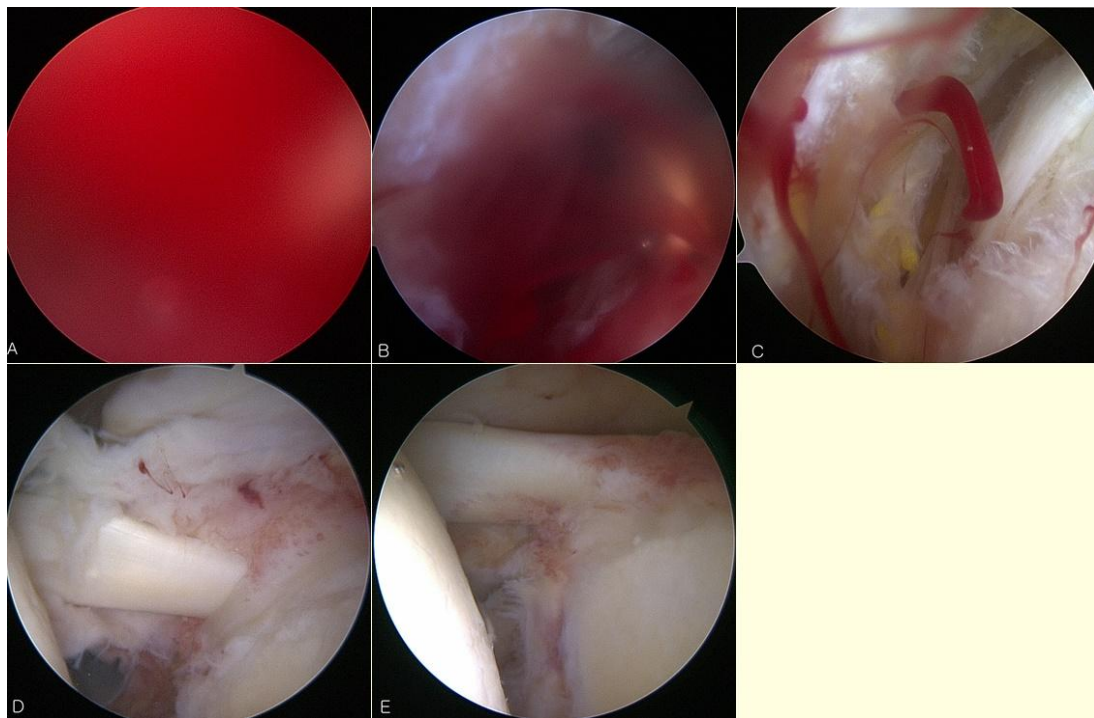


Figure 1. Arthroscopic view of the visual clarity scale.

(a) VCS 1; extremely poor, (b) VCS 2; poor, (c) VCS 3; acceptable, (d) VCS 4; good, (e) VCS 5; optimal.

Statistics

Except for the patient number, gender ratio (%), injured side, and frequency of use of additional analgesics, all of the measured values were denoted with their mean, ranges, and standard deviation. A statistical analysis was conducted using SPSS 17.0 for Windows (SPSS, Inc., Chicago, IL). A Chi-squared test of a Fisher's exact test was conducted for the sex and frequency of analgesics.) Changes in parameters (SBP, DBP, HR) over time were assessed using a mixed effects linear regression model (linear mixed model) to evaluate within- and between-group differences. A p-value < 0.05 was considered statistically significant.

Result

No significant difference in demographic factors was found between the groups (Table 3). No significant difference was observed between the groups in the overall surgical duration or for each surgical stage ($P=0.704$, Fig 2).

Blood pressure and heart rate began to increase from the start of surgical procedure and peaked at 5~10 minutes after the start of surgery, which also corresponds to the beginning of the acromioplasty in both groups. The values of SBP, DBP and HR were lower at all intraoperative time-points in the group B ($P<0.05$, Fig 3). The SBP, DBP and HR sharply increased and peaked at 5~10 minutes after the start of surgery, which is the initial period of acromioplasty procedure. After the hemodynamic peak, the blood pressure and the heart rate were decreased gradually and plateaued during the remained surgical procedure.

Table 3. Demographic data of the Patients

	Group A (n =73)	Group B (n=79)	P-value
Age	56.2yrs \pm 8.6	57.1yrs \pm 7.5	0.521
Sex (male/female)	40/33 (54.8%/45.2%)	39/40 (49.4%/50.6%)	0.503
Height	162.2cm \pm 7.5	160.1cm \pm 8.1	0.177
Weight	64.8kg \pm 8.9	62.8kg \pm 10.2	0.210
BMI	24.6 \pm 3.0	24.3 \pm 2.6	0.430
Injury side (Rt./Lt.)	54/25 (68.4%/31.6%)	53/20 (72.6%/24.7%)	0.567

Data are presented as the mean \pm standard deviation and numbers of patient.

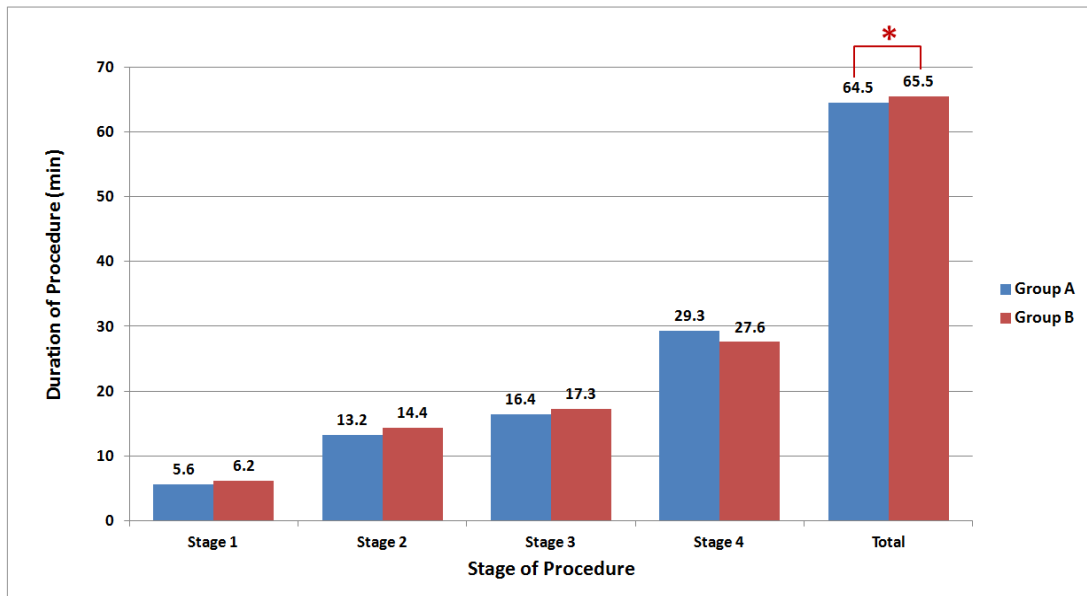


Figure 2. Duration of procedure.

Stage 1 : Intra-articular soft tissue procedure, Stage 2 : Acromioplasty, Stage 3 : Greater tuberosity and tendon preparation, Stage 4 : Tendon repair with suture bridge, Total : total surgical procedure. *P = 0.704

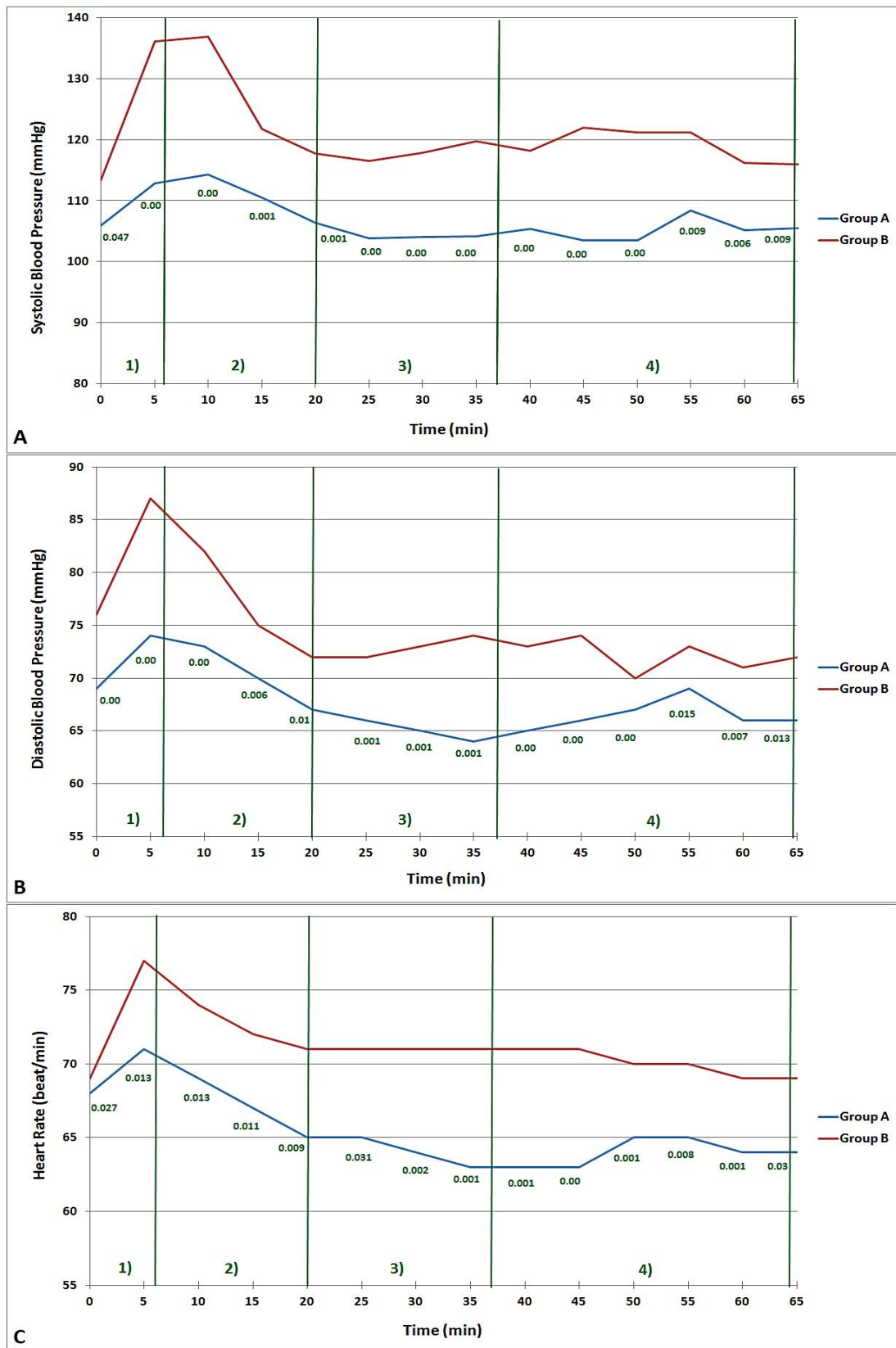


Figure 3. Changes in systolic blood pressure (a), diastolic blood pressure (b), and heart rate (c) during surgical procedure.

The frequency of administered analgesics during the surgical procedures were 0.19 ± 0.46 in group A, 0.53 ± 0.86 in group B and hypotensive agent were 0.67 ± 0.94 in group A, 0.85 ± 1.06 in group B. The frequency of administered analgesics was significantly higher in group B than in group A ($P=0.003$, Fig 4). However, no significant difference was found in administered hypotensive agents for hemodynamic stability between the groups ($P=0.287$, Fig 4). The VCS was significantly improved in group A at stage 2 ($P<0.001$) and stage 3 ($P=0.035$) of the surgical procedures. However, there was no significant difference at stage 1 ($P=0.713$) and stage 4 ($P=0.116$). No systemic adverse reactions resulting from the IBPB or surgical procedure were observed in either group.

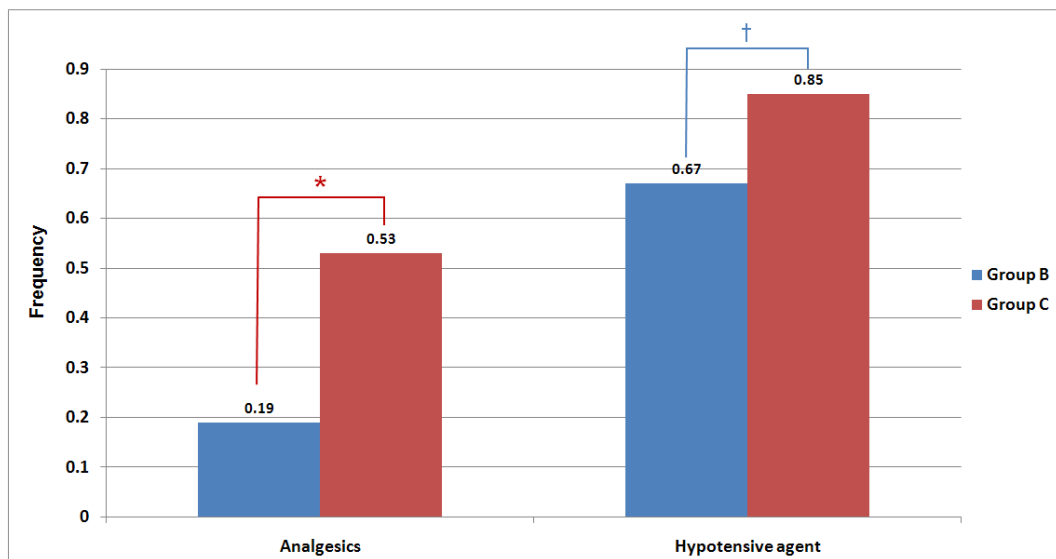


Figure 4. The frequency of administered medication.

Analgesics included fentanyl, Hypotensive agent included such as B-blocker and calcium channel blocker.

* $P=0.003$, † $P=0.287$

Discussion

The performing of an IBPB resulted in significant decreases in both the postoperative pain score and the administration of supplemental analgesia required in patients undergoing shoulder arthroscopic surgery^[12]. Shoulder surgery without regional anesthesia results in poor postoperative analgesia and high opioid usage^[13]. Many studies on IBPB have focused on post operative analgesic effects and the cost-effectiveness of alternative modalities of general anesthesia for shoulder surgeries. No study has compared the intraoperative effects of IBPB combined with general anesthesia with those of general anesthesia alone in patients undergoing shoulder arthroscopy. Additionally, we focused on the intraoperative effects of IBPB, such as the amount of bleeding, visualization quality, medications required for BP control and surgical duration.

There is a general consensus that IBPB is an effective way to preserve hemodynamic stability during arthroscopic shoulder surgery. Lee et al. reported that hemodynamic stability during surgical procedures was well maintained in the patients who had received an IBPB before shoulder arthroscopy^[14]. Our study revealed the study subjects who had received a preoperative IBPB were able to maintain lower blood pressure and heart rate, even without the frequent intraoperative administration of blood pressure-controlling medications and analgesic agents. When the operative view is impaired by bleeding, surgeons usually request that anesthesiologist keep the blood pressure low. Increased usage of hypotensive agents may lead to a higher occurrence of adverse effects, which in turn could be detrimental to patients with cardiovascular disease. Induced hypotension carries a risk of compromising cerebral perfusion to the extent that

clinically significant cerebral ischemia may occur, thus resulting in stroke, visual or neurologic sequelae, or death^[15]. IBPB could be an effective choice for reducing the intraoperative usage of hypotensive agents and its accompanying adverse effects.

To evaluate arthroscopic visualization, Jesen et al. used a surgeon-rated visual analog scale (VAS, 1 to 10) and the hemoglobin concentration of the irrigation fluid^[16]. Harris et al. used a 3-degree rating system (score 1 – no impairment of visualization, score 2 – some impairment during parts of the procedure, score 3 – significant impairment of visualization) to assess arthroscopic visualization^[1]. In our study, a five-point visual clarity rating scale was used to evaluate arthroscopic visualization, as scored by the surgeon according to surgical working conditions. We created a VCS system that clearly differentiated among the scores and is readily reproducible by other surgeons. As anticipated, the arthroscopic operative view evaluated with the VCS was clearer in patients who had undergone preoperative IBPB. The authors verified that IBPB is beneficial to achieving an adequate operative view after evaluating the effects of IBPB on intraoperative hemodynamic factors and VCS. If a clear visual field can be achieved with less bleeding during operative procedures, surgery will go more smoothly without any further unnecessary measures to control bleeding. We expected that establishing a clear visual field during surgery would result a shorter duration of surgical procedure. However, there was no significant difference in the duration of the overall surgical procedures.

The authors divided operative time into four stages according to the surgical procedures and tried to evaluate the characteristics of each stage. Distinctive elevation of both blood pressure and heart rate with peaks during the acromioplasty procedure was found after analyzing alterations of the

hemodynamic factors. Based on this finding, methods to improve the surgical view could include technically avoiding the features that would lead to hemodynamic alterations during acromioplasty or using preventive medications that may prevent blood pressure increases. Confirming whether the hemodynamic peak is relevant to acromioplasty procedure or is merely a common phenomenon that occurs approximately 5~10 minutes after the start of surgery remains to be seen. This confirmation could be achieved through further research with different operative procedures or performing acromioplasty at the end.

This study had the following limitations. First, we restricted the subject population to simple medium-sized tears only. Operative time can be affected by the size of the tear and could exert significant influence on the conclusions of this study. The small size tears were excluded from the database due to the relative simplicity of the surgery, short operative time and trivial impact on the comparison of operative time of each group. Large and massive tear sizes were also dropped out from the study because of their surgical variability and diverse surgical procedures that are based on tear shape, tendon involvement, and reparability, which cannot be generalized in calculating and comparing the outcomes. As a result, patients who underwent medium-sized rotator cuff repair were selected to be the optimal database due to the consistent surgical procedure and appropriate operation time to evaluate how IPBP can affect the surgery itself. However, the arthroscopic technique for medium tears is a relatively simple procedure. Additionally, the mean operative time was relatively short, and the procedures did not cause massive bleeding during the procedures. Second, we excluded patients with hypertension, cardiovascular disease and coagulation abnormalities. The patients excluded from this study were those who would tend to experience bleeding during arthroscopic surgery. We believe that these two limitations result

in an underestimation of the effects of IBPB. Therefore, further research including larger study populations with large to massive tears hypertension or cardiovascular disease would be necessary.

Third, in this study, VCS was classified according to the surgeon's subjective opinion. Classification with objective parameters would be necessary to reduce possible bias. According to the literature, collecting the total amount of saline that is used as an irrigant and determining its hemoglobin concentration were used to evaluate arthroscopic operative visibility^[16]. Further research with the abovementioned parameters can render more objective conclusions regarding whether preoperative IBPB has beneficial effects on obtaining a clear operative view.

Conclusion

Preoperative IBPB for arthroscopic rotator cuff repair was beneficial in maintaining hemodynamic stability without frequent intraoperative usage of medications. The arthroscopic operative view evaluated with VCS was improved in the preoperative IBPB 379 group in this study.

Reference

1. **Ogilvie-Harris DJ, Weisleder L.** Fluid pump systems for arthroscopy: a comparison of pressure control versus pressure and flow control. *Arthroscopy*, 1995;11:591-95. Doi: 10.2106/JBJS.L.01116
2. **Morrison DS, Schaefer RK, Friedman RL.** The relationship between subacromial space pressure, blood pressure, and visual clarity during arthroscopic subacromial decompression. *Arthroscopy* . 1995;11:557-60. Doi: 10.1097/ACO.0b013e32835069c2
3. **Sacco M, Meschi M, Regolisti G, Detrenis S, Bianchi L, Bertorelli M, Pioli S, Magnano A, Spagnoli F, Giuri PG, Fiaccadori E, Caiazza A.** The relationship between blood pressure and pain. *J Clin Hypertens*. 2013;15:600-5. Doi:10.1111/jch.12145
4. **Maixner W, Gracely RH, Zuniga JR, Humphrey CB, Bloodworth GR.** Cardiovascular and sensory responses to forearm ischemia and dynamic hand exercise. *Am J Physiol*. 1990 ;259:R1156-63. Doi: 10.1097/AAP.0b013e3181ada622
5. **Dahl JB, Moiniche S.** Pre-emptive analgesia. *Br Med Bull*. 2004;71:13-27. Doi:10.1093/bmb/ldh030
6. **Dalury DF, Lieberman JR, Macdonald SJ.** Current and innovative pain management techniques in total knee arthroplasty. *Instr Course Lect*. 2012;61:383-88. Doi: 10.1016/0749-8063(95)90131-0
7. **Lanna M, Pastore A, Policastro C, Iacovazzo C.** Anesthesiological considerations in shoulder surgery. *Transl Med UniSa*. 2012;3:42-8. Doi: 10.2106/JBJS.9320icl
8. **Brown AR, Weiss R, Greenberg C, Flatow EL, Bigliani LU.** Interscalene block for shoulder arthroscopy: comparison with general anesthesia. *Arthroscopy*. 1993;9:295-300. Doi: 10.1053/jars.2001.23590
9. **DeOrio JK, Cofield RH.** Results of a second attempt at surgical repair of a failed initial

rotator-cuff repair. *J Bone Joint Surg Am.* 1984;66:563-7. Doi: 10.1016/j.arthro.2007.03.093

10. Park SK, Choi YS, Choi SW, Song SW. A comparison of three methods for postoperative pain control in patients undergoing arthroscopic shoulder surgery. *Korean J Pain.* 2015;28:45-51. Doi:10.3344/kjp.2015.28.1.45

11. Choi S, Kim MK, Kim GM, Roh YH, Hwang IK, Kang H. Factors associated with clinical and structural outcomes after arthroscopic rotator cuff repair with a suture bridge technique in medium, large, and massive tears. *J Shoulder Elbow Surg Am.* 2014;23:1675-81. Doi: 10.1016/j.jse.2014.02.021

12. Hughes MS, Matava MJ, Wright RW, Brophy RH, Smith MV. Interscalene brachial plexus block for arthroscopic shoulder surgery: a systematic review. *J Bone Joint Surg Am.* 2013;95:1318-24. Doi:10.2106/JBJS.L.01116

13. Sulaiman L, Macfarlane RJ, Waseem M. Current concepts in anaesthesia for shoulder surgery. *Open Orthop J.* 2013;7:323-8. Doi:10.2174/1874325001307010323

14. Lee HY, Kim SH, So KY, Kim DJ. Effects of interscalene brachial plexus block to intra-operative hemodynamics and postoperative pain for arthroscopic shoulder surgery. *Korean J Anesthesiol.* 2012;62:30-4. Doi:10.4097/kjae.2012.62.1.30

15. Lee JH, Min KT, Chun YM, Kim EJ, Choi SH. Effects of beach-chair position and induced hypotension on cerebral oxygen saturation in patients undergoing arthroscopic shoulder surgery. *Arthroscopy.* 2011;27:889-94. Doi:10.1016/j.arthro.2011.02.027

16. Jensen KH, Werther K, Stryger V, Schultz K, Falkenberg B. Arthroscopic shoulder surgery with epinephrine saline irrigation. *Arthroscopy.* 2001;17:578-81. Doi:10.1053/jars.2001.23590