

# Evaluation of Carotid Atherosclerosis Using Three-Phase CT<sup>1</sup>

In Young Kim<sup>1</sup>, Sun Young Jeong<sup>2</sup>, Ji Kang Park<sup>2</sup>

<sup>1</sup>Jeju National University School of Medicine,

<sup>2</sup>Department of Radiology, Jeju National University School of Medicine, Jeju, Korea

(Received July 18, 2013; Revised July 25, 2013; Accepted July 31, 2013)

## Abstract

**Purpose :** Carotid atherosclerotic plaque (CAP) was evaluated by three-phase CT (TPCT; CT<sub>pre</sub>, CT<sub>artery</sub>, CT<sub>delay</sub>). The purposes of this study are to: (1) to determine optimal phase for the visualization of CAP components; (2) evaluate whether there is a significant difference in the quantitative CT Hounsfield unit (CTHUs) of the CAP components between the arterial and delay phase.

**Materials and Methods :** Two reviewers evaluated the detection rate and image quality for CAP components on CT<sub>artery</sub> and CT<sub>delay</sub> source images in 36 patients. Quantitative analysis of the CTHUs for the soft plaque and outer wall was performed in 47 arteries. The CTHUs were measured for the soft plaque and the outer wall using the manual ROI method for each carotid plaque. The difference of image quality on CT<sub>artery</sub> and CT<sub>delay</sub>, the difference of the CTHUs according to CT phase, the difference in CTHUs according to the arterial symptomatology or stenosis degree were statistically evaluated.

**Results :** CT<sub>delay</sub> was the optimal phase for the delineation of soft plaque and outer wall enhancement. The CAP components showed progressive delayed enhancement. There were statistically significant increase in the enhancement of the outer wall through TPCT ( $p < 0.001$ ). CTHUs of soft plaque and outer wall on CT<sub>delay</sub> and CT<sub>artery</sub> did not show significant correlations with symptomatology. The CTHUs of soft plaque on CT<sub>artery</sub> ( $p = 0.02$ ) and CTHUs of the outer wall on CT<sub>delay</sub> ( $p = 0.01$ ) were significantly higher in the group of symptomatic arteries or severely stenotic arteries together than that in the group of asymptomatic arteries with less than 70% stenosis.

**Conclusion :** CT<sub>delay</sub> was the optimal phase for plaque detection and the characterization of plaque components. (J Med Life Sci 2013;10(2):94-100)

**Key Words :** CT, Carotid artery, Atherosclerotic plaque

## Introduction

Carotid atherosclerotic plaque (CAP) is one of major and preventable causes of ischemic cerebral stroke. Early clinical studies revealed that the degree of stenosis and symptomatology are the most important prognostic factor of carotid atherosclerosis in predicting the risk of future strokes (1-3). It was shown that carotid endarterectomy is beneficial in symptomatic patients with stenosis greater than 70% (4). However, there have been debates about whether a revascularization procedure is beneficial in patients with asymptomatic high grade stenosis or in symptomatic patients with moderate stenosis (5, 6). The dynamic natural course of atherosclerotic plaque and the role of inflammation in the progression of atherosclerotic plaque have been identified,

and the concept of vulnerable plaque has been introduced (7-10). Vulnerable plaques, which are prone to rupture, have the following characteristics: high inflammatory cellular infiltration, thin or ruptured fibrous cap, fresh luminal thrombus near the CAP, a large LRNC, stenosis greater than 90%, and intraplaque hemorrhage (11-13). To detect these characteristics, MRI has been widely used in CAP imaging. MRI can display CAP with sufficiently high spatial resolution to measure accurate plaque volume and can differentiate CAP components, such as a fibrous caps, LRNC, and intraplaque hemorrhage (14, 15). In addition, MRI can assess the burden of inflammatory cell infiltration within the plaque using a macrophage-specific contrast agent (16, 17). In contrast to MRI, CT has not been widely used in CAP imaging due to its limited soft tissue contrast. However, recent CT studies using CT angiography (CTA) and its source image have revealed a potential role of CT for plaque imaging. Despite the overlap and the variable range of CT Hounsfield unit (CTHU), these studies revealed that plaque components such as LRNC, fibrous tissue, and

Correspondence to : Ji Kang Park  
Department of Radiology, Jeju National University Hospital,  
Jeju National University School of Medicine,  
1753-3, Ara-1-dong, JEJU-SI, Jeju 690-767, Republic of Korea  
E-mail : jkcontrast@naver.com

hemorrhage could be characterized according to CTHU (18, 19).

Recent investigation revealed that neoangiogenesis within the CAP is a marker of plaque vulnerability and is associated with intraplaque hemorrhage, necrosis, and inflammatory cell infiltration (20–22). Neoangiogenesis arises from the vasa vasorum of the adventitial layer (22). Neoangiogenesis has been evaluated by MRI and US with contrast agent, and the density and characteristics of neoangiogenesis have been evaluated by DCE-MRI. Adventitial (carotid outer wall)  $K^{trans}$  showed a good correlation with the amount of neoangiogenesis and the degree of macrophage infiltration (23, 24). The carotid outer wall showed progressive and delayed enhancement in DCE-MRI studies and dynamic MR wall imaging, and the peak enhancement occurred nearly three minutes after contrast agent administration (24, 25). CTA has become one of the first-line methods for the evaluation of carotid atherosclerosis; however, dynamic CTA are limited due to the problem of radiation exposure, and there have been no reports on dynamic CTA. CTA is usually performed with a single arterial phase or two phases, including a precontrast and arterial phase, for bone subtraction. In this study, we tried three-phase CT (TPCT) for CAP imaging as follows:  $CT_{pre}$ ,  $CT_{artery}$ , and  $CT_{delay}$  with three minutes after contrast agent administration.

The purposes of this study are to: (1) to determine which phase is better in depicting carotid plaque components; (2) assess the pattern of contrast enhancement in the CAP component by measuring quantitative CTHUs in  $CT_{artery}$  and  $CT_{delay}$  phase; (3) evaluate whether there is a significant difference in the quantitative CTHUs of the CAP components according to symptomatology or joint grouping of symptomatology or severe stenosis of greater than 70%.

## Materials and Methods

This study was approved by the local research committee, and all patients gave written informed consent prior to inclusion. From May 2008 to October 2008, 102 patients were consecutively enrolled. TPCT studies were performed for the screening of carotid atherosclerosis or the evaluation of vascular lesions in patients with recent ischemic cerebral stroke. Among these 102 patients, 66 were excluded because of the absence of carotid plaque in both carotid arteries, and 36 patients were finally included in this study ( $69.4 \pm 10.4$ , M:F=27:9). Risk factors for atherosclerosis were as follows: diabetes mellitus 38.9% (14/36), hypertension

11.1% (4/36), hyperlipidemia 22.2% (8/36), and heavy smoking greater than 20 packs/year 11.1% (4/36). A recent cerebral ischemic event within one month of the CT study had occurred in 10 patients, and CAP in 10 arteries was associated with recent ischemic stroke in the arterial territory of the ipsilateral cerebral hemisphere. These arteries were regarded as symptomatic arteries.

## Image acquisition

CTA was performed with a 16-detector row CT scanner (Sensation 16; Siemens, Erlangen, Germany). Patients were positioned supine with their arms along the chest on the CT table. The scan range reached from the ascending aorta to the skull base or the circle of Willis level (2 cm above the sella) for  $CT_{pre}$  and  $CT_{artery}$ . The arterial phase was determined by real-time bolus tracking, and the delay phase was acquired three minutes after contrast agent administration. For  $CT_{delay}$ , the center slice was positioned at the level of the angle of the mandible angle, and the z-axis coverage was set to 8 cm. 80 to 100 mL of nonionic contrast agent (Ultravist 370; Schering, Berlin, Germany) was injected with a power injector at a rate of 4 mL/s followed by a saline flush of 50 mL. The right antecubital vein was preferentially used. Scanning parameters were 0.75-mm collimation, 12-mm (pitch of 1) table feed per rotation, 0.5-second rotation time, 120 kV, and 160–180 mAs. Additional CTDIvol for  $CT_{delay}$  was  $5.6 \pm 0.3$  mGy. Sections were reconstructed with 1.0 mm increments and a soft convolution kernel (B20).

## Image analysis

The  $CT_{artery}$  and  $CT_{delay}$  source images were retrospectively analyzed by two radiologists. Carotid artery stenosis on  $CT_{artery}$  was measured by Reviewer 1 on a workstation (Leonardo, Siemens) using the standard NASCET method<sup>4</sup>. Both reviewers independently evaluated the presence of carotid plaques near the carotid bifurcation on  $CT_{artery}$  and  $CT_{delay}$  source image. Each phase of the source images were reviewed separately in three sessions at one-week intervals and was independently assessed by the two reviewers. Carotid plaque components were classified by visual assessment of CT morphology and CTHUs as follows. Soft plaque was defined by a low density on  $CT_{artery}$  and  $CT_{delay}$  and CTHUs between 0 and 70. The carotid outer wall was identified by enhancement on  $CT_{artery}$  and  $CT_{delay}$ . Then the reviewers evaluated the detection rate and overall image

quality for the depiction of carotid plaque components on the CT<sub>artery</sub>, and CT<sub>delay</sub> using the following scales comparing CT<sub>artery</sub> and CT<sub>delay</sub> source image. For soft plaque: 0 for no visible soft plaque, 1 for suspicious soft plaque with luminal contour change, and 2 for clearly visible low-density soft plaque. For carotid outer wall: 0 for less than 20% visible fractions of the normal wall circle, 1 for 20 to 50% visible fractions of the normal wall circle, and 2 for more than 50% visible fractions of the normal wall circle. Thirdly, Quantitative analysis based on the CTHUs of soft plaque and the outer wall was performed. We included the arteries with the CAP that had a measurable area of soft plaque on CT<sub>delay</sub>, and 47 carotid arteries were evaluated for ROI analysis. Reviewer 1 measured the CTHU at the soft plaque and outer wall in 1 to 3 slices according to plaque burden with a manual ROI method at each CAP. For soft plaque CTHUs, a ROI covering 50 to 80 pixels was drawn in the central part of the soft plaque in the same position on the CT<sub>artery</sub>, and CT<sub>delay</sub> source images. For the CTHUs of the outer wall, a ROI covering 3 to 10 pixels was drawn in the same position on the CT<sub>artery</sub>, and CT<sub>delay</sub> source images. In the analysis of soft plaque in 37 asymptomatic arteries, 5 arteries in CT<sub>artery</sub> were excluded because reliable ROI measurement was difficult due to the small size and indistinct visualization of the soft plaque. In the analysis of the outer wall in 37 asymptomatic arteries, 6 arteries in CT<sub>artery</sub>, 2 arteries in CT<sub>delay</sub> were excluded for the same reason.

### Statistical analysis

Interobserver variability in interpreting the detection rate and the quality of the images was calculated with  $\kappa$  statistics using SPSS version 15.0, with  $\kappa \geq 0.80$  defined as excellent agreement,  $\kappa = 0.60$  to 0.79 as good agreement, and  $\kappa = 0.50$  to 0.59 as moderate agreement. The significant difference in the quality of CT images in each phase for depiction of carotid plaque components was determined with Friedman two-way analysis of variance by ranks. The differences of the CTHUs according to CT phase in each artery were assessed using paired t-test. To evaluate the difference in CTHUs according to the arterial symptomatology or grouping of symptomatology or severe stenosis greater than 70% together versus asymptomatic arteries with stenosis less than 70%, independent t-tests were performed for soft plaque and the outer arterial wall. When we used 70% stenosis as the criteria, 5 arteries were added to the 10

symptomatic arteries. The normality assumption was verified using the Shapiro-Wilk test. Statistical significance was defined at an alpha level of  $p < 0.05$ , two tailed. SPSS (SPSS Inc., Chicago, IL) statistical software was used for all computations.

### Results

The mean degree of stenosis in the 47 arteries was  $57.5\% \pm 31.5$ , and the mean degree of stenosis in the 10 symptomatic arteries was  $84.4\% \pm 16.5$ . The degree of stenosis in the 5 asymptomatic arteries with stenosis greater than 70% was  $74.2 \pm 5.9\%$ . The mean stenosis in the 32 arteries with stenosis less than 70% was  $29.2 \pm 18.4\%$ . For both observers, CAP was more frequently detected in CT<sub>delay</sub> images than in CT<sub>artery</sub> images (Table 1).

Table 1. Results of carotid plaque detection in CT<sub>artery</sub> and CT<sub>delay</sub> phase source image.


Reviewer	CT phase			Total
	CT <sub>artery</sub>	CT <sub>delay</sub>	Neg	
1	60	64	8	72
2	60	63	9	72

Interobserver agreement for the detection of CAP in CT<sub>artery</sub> and CT<sub>delay</sub> source image was excellent. For overall image quality, CT<sub>delay</sub> images were statistically superior to the CT<sub>artery</sub> images for the delineation of carotid plaque components (Table 2).

Table 2. Results of the image quality of source images from CT<sub>artery</sub> and CT<sub>delay</sub> for depicting carotid plaque components.

Reviewer	CT phase		P-value
	CT <sub>artery</sub>	CT <sub>delay</sub>	CT <sub>artery</sub> /CT <sub>delay</sub>
Reviewer 1			
Soft plaque	0.95±0.90	1.51±0.84	<0.001
Outer wall	0.56±0.75	1.36±0.79	<0.001
Reviewer 2			
Soft plaque	1.03±0.87	1.37±0.86	<0.001
Outer wall	1.26±0.76	1.52±0.75	<0.001

CT<sub>delay</sub> was the better than CT<sub>artery</sub> for the delineation of soft plaque and outer wall enhancement for all reviewers (Figure 1). Interobserver agreement for the image quality when depicting the components of CAP was as follows: good in CT<sub>delay</sub> for soft plaque ( $\kappa = 0.69$ ), and moderate in



**Figure 1.** Depiction of carotid plaque on TPCT. CT<sub>delay</sub> is the best phase for the depiction of the soft plaque and outer wall among the three phases.

CT<sub>delay</sub> for the outer wall ( $\kappa = 0.56$ ) and in CT<sub>artery</sub> for soft plaque depiction ( $\kappa = 0.53$ ). There were statistically significant differences of the contrast enhancement in the

outer wall between CT<sub>artery</sub> and CT<sub>delay</sub> images (p-value < 0.001, Table 3).

**Table 3.** Comparison of the CTHUs of the soft plaque and the outer wall in TPCT source image from each phase.

Reviewer	CT phase		P-value
	CT <sub>artery</sub>	CT <sub>delay</sub>	CT <sub>artery</sub> VS. CT <sub>delay</sub>
Soft plaque	37.7±14.2	41.0±18.9	0.07
Outer Wall	49.3±12.7	71.7±20.1	<0.001

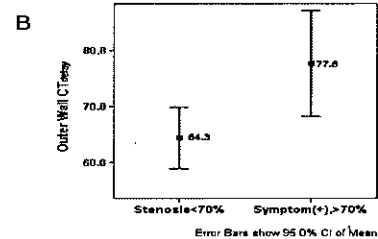

The outer wall showed more prominent enhancement in CT<sub>delay</sub> than in CT<sub>artery</sub>. The difference in CTHUs of soft plaque enhancement was not significant between CT<sub>artery</sub> and CT<sub>delay</sub>. CTHUs of soft plaque and the outer wall on CT<sub>delay</sub> and CT<sub>artery</sub> did not show significant correlations with group membership of arterial symptomatology (Table 4).

**Table 4.** Comparison of the CTHUs between symptomatic and asymptomatic arteries.

Reviewer	Soft Plaque			Outer Wall		
	Symptom(+)	Symptom(-)	p-value	Symptom(+)	Symptom(-)	p-value
CT <sub>artery</sub>	41.7±10.8	35.7±14.6	0.24	52.9±11.9	47.6±12.9	0.26
CT <sub>delay</sub>	43.2±13.5	39.2±15.9	0.48	73.8±11.8	67.4±17.4	0.28

The CTHUs of soft plaque on CT<sub>artery</sub> (P=0.02) and CTHUs of the outer wall on CT<sub>delay</sub> (P=0.01) were significantly higher in the group of symptomatic arteries or severely stenotic

arteries together that the CTHUs in the group of asymptomatic arteries with less than 70% stenosis (Figure 2, Table 5).



**Figure 2.** The difference in the CTHUs of the outer wall between symptomatic/severe stenotic arteries (greater than 70% stenosis) and asymptomatic arteries with stenosis less than 70%. (A) The outer wall of an asymptomatic artery has a nodular calcification and thin wall with mild enhancement (left column, arrow, CTHU 65). The outer wall of a symptomatic artery has well enhancement (right column, arrow, CTHU 83). (B) Symptomatic or severe stenotic arteries show significantly greater enhancement in the outer wall than asymptomatic arteries with stenosis less than 70% (P=0.01).

**Table 5.** Comparison of the CTHUs between symptomatic/severely stenotic arteries and asymptomatic arteries with stenosis less than 70%.

Reviewer	Soft Plaque			Outer Wall		
	Symptom(+)	Symptom(-)	p-value	Symptom(+)	Symptom(-)	p-value
	Stenosis>70	Stenosis>70		Stenosis>70	Stenosis>70	
CT <sub>artery</sub>	43.8±11.9	33.3±13.6	0.02	53.5±11.8	46.2±12.6	0.08
CT <sub>delay</sub>	45.8±13.7	37.3±15.5	0.08	77.6±17.0	64.3±14.3	0.01

## Discussion

In previous CT-based studies from the symptomatic patients, plaque composition was evaluated according to CTHUs in arterial phase source images; the CTHUs of LRNC ranged from 22.9 to 32.6, and the CTHUs of fibrous tissue ranged from 46.4 to 52.9 (18, 19). In terms of CTHUs, the soft plaque in our study may correspond to the mixture of LRNC and fibrous tissue in the previous CT studies. In this study, the component of the CAP showed progressive and delay enhancement. Delayed enhancement is defined as an increase of wall enhancement that occurs several minutes after contrast infusion in comparison with the degree of enhancement of the arterial phase. Delayed enhancement of the arterial wall has been reported in coronary plaque MRI and aortic aneurysm CT study. Delayed enhancement was associated with the severity of luminal stenosis and plaque calcification in coronary atherosclerosis (26) and was associated with a significantly larger diameter and atheromatous burden as well as a higher level of CRP in abdominal aortic aneurysms (27). The mechanism of delayed enhancement is thought to be increased interstitial space and delayed contrast wash-out in tissues supplied by fine microvessels (27, 28). The blood flow of the atherosclerotic plaque is mainly supplied by the adventitial vasa vasorum and neoangiogenic microvessels from the vasa vasorum, and the necrotic core has abundant interstitial space. Therefore, the enhancement of the outer wall and soft plaque is probably representative of delayed enhancement. In this study, CT<sub>delay</sub> was the optimal phase for the detection and delineation of soft plaque and the enhancement of the outer wall. The difference in CTHUs between soft plaque and outer wall was progressively increased through TPC<sub>T</sub> and was greatest on CT<sub>delay</sub>, and this large CTHUs difference on CT<sub>delay</sub> might grant better soft tissue contrast and higher detection rate of the CAP to CT<sub>delay</sub> images.

It has been shown that the degree of neoangiogenesis can be assessed by quantitative or semiquantitative analysis of

the enhancement pattern in the outer wall of the carotid artery in DCE-MRI and CTA studies (24, 29). According to these results, it would be possible to determine whether the plaque is vulnerable by analyzing the enhancement pattern of the outer wall. In our study, outer wall enhancement showed a similar pattern to that in the previous DCE-MRI study and showed progressive and delayed enhancement regardless of symptomatology or degree of stenosis; however, the degree of contrast enhancement in the outer wall was not significantly different between symptomatic and asymptomatic arteries. When symptomatic arteries or arteries with stenosis greater than 70% were grouped together, the degree of enhancement in the outer wall was significantly greater than that in asymptomatic arteries with stenosis of less than 70%. Symptomatology is a clinical criterion and is dependent on the time point of the events; in contrast, the vulnerability of the plaque is a pathological criterion and is dependent on histological characteristics (30). Asymptomatic arteries with severe stenosis of greater than 70% in our study might have had the features of vulnerable plaque, which might have affected the statistical results of the groups according to the symptomatology. In the previous DCE-MRI and CTA studies, the pattern of contrast enhancement was significantly different for the group with the symptomatic or severe stenotic arteries together but not in the pure symptomatic group (24, 29). In our study, the CTHUs of soft plaque on CT<sub>artery</sub> were significantly higher in symptomatic arteries and arteries with stenosis greater than 70% than that in asymptomatic arteries with stenosis less than 70%. In previous report of coronary arteries, vulnerable plaque had significantly greater iron deposition from the extravasated erythrocytes and greater macrophage infiltration compared to plaque with early-stage CAP, which was presumed to be due to repeated microhemorrhage from leaky microvessels within CAP(31). The higher CTHUs of soft plaque in symptomatic and severe stenotic arteries in our study may reflect the presence of repeated microhemorrhage.

Our study has several limitations. This study was based on a small sample group without histological correlation. We did not routinely apply TPCT to all CTA studies due to the problem of additional radiation. The lens of the eye is a radiation-sensitive organ. For radiation dose reduction to the lens, we can use bismuth eye shielding or special CT algorithm for dose reduction such as angular tube current modulation and automatic z-axis dose modulation (32-34). In this study, the CTHUs of the soft plaque and outer wall were measured in only one location per slice by drawing the ROI manually. Measurement by manual ROI may be accurate if the ROI is drawn at the exact lesion site; however, the reproducibility may be inferior to automatic or semiautomatic ROI measurement.

In conclusion, CT<sub>delay</sub> was the optimal phase for the detection and characterization of the CAP components. CAP components showed progressive and delayed enhancement on TPCT, and the outer wall showed more prominent enhancement than soft plaque. CTHUs of the outer wall on CT<sub>delay</sub> and soft plaque on CT<sub>artery</sub> were significantly higher in symptomatic or severely stenotic arteries.

## References

- 1) Autret A, Pourcelot L, Saudeau D, Marchal C, Bertrand P, de Boisvilliers S. Stroke risk in patients with carotid stenosis. *Lancet* 1987;1:888-890
- 2) Meissner I, Wiebers DO, Whisnant JP, O'Fallon WM. The natural history of asymptomatic carotid artery occlusive lesions. *JAMA* 1987;258:2704-2707
- 3) Dennis MS, Bamford JM, Sandercock PA, Warlow CP. A comparison of risk factors and prognosis for transient ischemic attacks and minor ischemic strokes. The Oxfordshire Community Stroke Project. *Stroke* 1989;20:1494-1499
- 4) Rigamonti D, Johnson PC, Spetzler RF, Hadley MN, Drayer BP. Cavernous malformations and capillary telangiectasia: a spectrum within a single pathological entity. *Neurosurgery* 1991;28:60-64
- 5) Endarterectomy for asymptomatic carotid artery stenosis. Executive Committee for the Asymptomatic Carotid Atherosclerosis Study. *JAMA* 1995;273:1421-1428
- 6) Rothwell PM, Eliasziw M, Gutnikov SA, Fox AJ, Taylor DW, Mayberg MR, et al. Analysis of pooled data from the randomised controlled trials of endarterectomy for symptomatic carotid stenosis. *Lancet* 2003;361:107-116
- 7) Glagov S, Weisenberg E, Zarins CK, Stankunavicius R, Kolettis GJ. Compensatory enlargement of human atherosclerotic coronary arteries. *N Engl J Med* 1987;316:1371-1375
- 8) Ambrose JA, Tannenbaum MA, Alexopoulos D, Hjemdahl-Monsen CE, Leavy J, Weiss M, et al. Angiographic progression of coronary artery disease and the development of myocardial infarction. *J Am Coll Cardiol* 1988;12:56-62
- 9) Moreno PR, Falk E, Palacios IF, Newell JB, Fuster V, Fallon JT. Macrophage infiltration in acute coronary syndromes. Implications for plaque rupture. *Circulation* 1994;90:775-778
- 10) Moreno PR, Bernardi VH, Lopez-Cuellar J, Murcia AM, Palacios IF, Gold HK, et al. Macrophages, smooth muscle cells, and tissue factor in unstable angina. Implications for cell-mediated thrombogenicity in acute coronary syndromes. *Circulation* 1996;94:3090-3097
- 11) Jander S, Sitzer M, Schumann R, Schroeter M, Siebler M, Steinmetz H, et al. Inflammation in high-grade carotid stenosis: a possible role for macrophages and T cells in plaque destabilization. *Stroke* 1998;29:1625-1630
- 12) Spagnoli LG, Mauriello A, Sangiorgi G, Fratoni S, Bonanno E, Schwartz RS, et al. Extracranial thrombotically active carotid plaque as a risk factor for ischemic stroke. *JAMA* 2004;292:1845-1852
- 13) Saam T, Hatsukami TS, Takaya N, Chu B, Underhill H, Kerwin WS, et al. The vulnerable, or high-risk, atherosclerotic plaque: noninvasive MR imaging for characterization and assessment. *Radiology* 2007;244:64-77
- 14) Yuan C, Mitsumori LM, Beach KW, Maravilla KR. Carotid atherosclerotic plaque: noninvasive MR characterization and identification of vulnerable lesions. *Radiology* 2001;221:285-299
- 15) Chu B, Kampschulte A, Ferguson MS, Kerwin WS, Yarnykh VL, O'Brien KD, et al. Hemorrhage in the atherosclerotic carotid plaque: a high-resolution MRI study. *Stroke* 2004;35:1079-1084
- 16) Trivedi RA, Mallawarachi C, JM UK-I, Graves MJ, Horsley J, Goddard MJ, et al. Identifying inflamed carotid plaques using in vivo USPIO-enhanced MR imaging to label plaque macrophages. *Arterioscler Thromb Vasc Biol* 2006;26:1601-1606
- 17) Tang TY, Howarth SP, Miller SR, Graves MJ, JM UK-I, Li ZY, et al. Correlation of carotid atheromatous plaque inflammation using USPIO-enhanced MR imaging with degree of luminal stenosis. *Stroke* 2008;39:2144-2147
- 18) de Weert TT, Ouhlous M, Meijering E, Zondervan PE, Hendriks JM, van Sambeek MR, et al. In vivo characterization and quantification of atherosclerotic

- carotid plaque components with multidetector computed tomography and histopathological correlation. *Arterioscler Thromb Vasc Biol* 2006;26:2366-2372
- 19) Wintermark M, Jawadi SS, Rapp JH, Tihan T, Tong E, Glidden DV, et al. High-resolution CT imaging of carotid artery atherosclerotic plaques. *AJNR Am J Neuroradiol* 2008;29:875-882
- 20) de Boer OJ, van der Wal AC, Teeling P, Becker AE. Leucocyte recruitment in rupture prone regions of lipid-rich plaques: a prominent role for neovascularization? *Cardiovasc Res* 1999;41:443-449
- 21) McCarthy MJ, Loftus IM, Thompson MM, Jones L, London NJ, Bell PR, et al. Angiogenesis and the atherosclerotic carotid plaque: an association between symptomatology and plaque morphology. *J Vasc Surg* 1999;30:261-268
- 22) Virmani R, Kolodgie FD, Burke AP, Finn AV, Gold HK, Tulenko TN, et al. Atherosclerotic plaque progression and vulnerability to rupture: angiogenesis as a source of intraplaque hemorrhage. *Arterioscler Thromb Vasc Biol* 2005;25:2054-2061
- 23) Kerwin WS, O'Brien KD, Ferguson MS, Polissar N, Hatsukami TS, Yuan C. Inflammation in carotid atherosclerotic plaque: a dynamic contrast-enhanced MR imaging study. *Radiology* 2006;241:459-468
- 24) Kerwin WS, Oikawa M, Yuan C, Jarvik GP, Hatsukami TS. MR imaging of adventitial vasa vasorum in carotid atherosclerosis. *Magn Reson Med* 2008;59:507-514
- 25) Aoki S, Aoki K, Ohsawa S, Nakajima H, Kumagai H, Araki T. Dynamic MR imaging of the carotid wall. *J Magn Reson Imaging* 1999;9:420-427
- 26) Yeon SB, Sabir A, Clouse M, Martinezclark PO, Peters DC, Hauser TH, et al. Delayed-enhancement cardiovascular magnetic resonance coronary artery wall imaging: comparison with multislice computed tomography and quantitative coronary angiography. *J Am Coll Cardiol* 2007;50:441-447
- 27) Sakuta A, Kimura F, Aoka Y, Aomi S, Hagiwara N, Kasanuki H. Delayed enhancement on computed tomography in abdominal aortic aneurysm wall. *Heart Vessels* 2007;22:79-87
- 28) Klein C, Schmal TR, Nekolla SG, Schnackenburg B, Fleck E, Nagel E. Mechanism of late gadolinium enhancement in patients with acute myocardial infarction. *J Cardiovasc Magn Reson* 2007;9:653-658
- 29) Romero JM, Babiarz LS, Forero NP, Murphy EK, Schaefer PW, Gonzalez RG, et al. Arterial wall enhancement overlying carotid plaque on CT angiography correlates with symptoms in patients with high grade stenosis. *Stroke* 2009;40:1894-1896
- 30) Takaya N, Yuan C, Chu B, Saam T, Underhill H, Cai J, et al. Association between carotid plaque characteristics and subsequent ischemic cerebrovascular events: a prospective assessment with MRI--initial results. *Stroke* 2006;37:818-823
- 31) Kolodgie FD, Gold HK, Burke AP, Fowler DR, Kruth HS, Weber DK, et al. Intraplaque hemorrhage and progression of coronary atheroma. *N Engl J Med* 2003;349:2316-2325
- 32) Ryu CW, Kim JK, Kim SJ, Lee JH, Kim JH, Ha HI, et al. Head and neck vascular lesions: characterization of the flow pattern by the use of three-phase CT. *Korean J Radiol* 2009;10:323-332
- 33) Namasivayam S, Kalra MK, Pottala KM, Waldrop SM, Hudgins PA. Optimization of Z-axis automatic exposure control for multidetector row CT evaluation of neck and comparison with fixed tube current technique for image quality and radiation dose. *AJNR Am J Neuroradiol* 2006;27:2221-2225
- 34) van Straten M, Deak P, Shrimpton PC, Kalender WA. The effect of angular and longitudinal tube current modulations on the estimation of organ and effective doses in x-ray computed tomography. *Med Phys* 2009;36:4881-4889